

CASE REPORT

Asymptomatic Myxomatous Degeneration of the Mitral Valve, in a Young Male

Carmen Opris^{1*}, Horatiu Suci^{1,2}, Catalin Satala³, Cosmin Banceu², Cosmin Opris¹, Alexandra Stoica², Tudor Capilna², Simona Gurzu^{3,4}

1. Department of Adult and Children Cardiovascular Recovery, Emergency Institute for Cardio-Vascular Diseases and Transplantation, Targu Mures, Romania

2. Department of Surgery, George Emil Palade University of Medicine, Pharmacy, Sciences and Technology, Targu Mures, Romania

3. Department of Pathology, George Emil Palade University of Medicine, Pharmacy, Sciences and Technology, Targu Mures, Romania

4. Research Center (CCAMF), George Emil Palade University of Medicine, Pharmacy, Sciences and Technology, Targu Mures, Romania

Background: In young patients, the most common cause of mitral valve regurgitation is prolapse or flail of the valve, which is morphologically reflected by myxomatous degeneration. In rare cases, such this presented in this paper, this lesion might be incidentally identified, in young people. **Case presentation:** A 43-year-old male, with familial history of hypertension, presented in our Department of Cardiology for a routine check-up. Despite of lack of symptoms, an intense murmur was detected at mitral auscultation area. The echocardiography revealed a severe mitral regurgitation caused by flail of posterior mitral valve. The patient was transferred to the Cardiac Surgery Department for surgical intervention consisting in mitral valve repair. The histopathological examination revealed severe myxomatous degeneration of the spongiosa and fibrosa layers. The recovery after surgery was very good with no postoperative complications. The patient was discharged seven days after surgery, with no significant mitral regurgitation at the three-month follow-up. **Conclusions:** In young, asymptomatic patients, the proper time for mitral valve repair should be decided by an interdisciplinary team. For a better understanding of myxomatous degeneration particularities, histopathological assessment should be done in any replaced valve. Certification of such lesions, under microscope, might be an indicator for familial cardiovascular screening, in first degree relatives.

Keywords: mitral valve, mitral regurgitation, myxomatous degeneration, surgery, histology

Received 25 March 2020 / Accepted 29 July 2020

Introduction

After aortic stenosis, mitral insufficiency is the second most common reason for cardiac surgery. Mitral valve regurgitation is the most frequent indication for mitral valve repair [1]. The incidence of mitral regurgitation in the general population is about 2.4%, whereas moderate-to-severe regurgitation appears in 1.7% of people [1-3]. Only 0.6% in young adults are diagnosed with mitral valve regurgitation [4]. As some of these patients are asymptomatic, such as in the case presented in this paper, they are identified in late stages, with associated complications, like high pulmonary pressure.

In young patients, severe mitral regurgitation is usually induced by prolapse and/or flail of the mitral valve due to myxomatous degeneration, rheumatic heart disease, infective endocarditis, collagen vascular disease (e.g. Marfan syndrome), medications (e.g. anorectic drugs), etc. [2]. Myxomatous degeneration can be diagnosed under microscope and is believed to occur as a result of abnormal synthesis of type IV collagen [2-3]. As the removed valves are not always sent for microscopic evaluation, the incidence of this degeneration is unknown [2].

In this paper we present the case of a 43-year-old asymptomatic male, who was incidentally diagnosed with severe mitral regurgitation and successfully treated by surgical

mitral valve repair. An advanced myxomatous degeneration was diagnosed at histopathological examination. For this case report, we obtained the signed informed consent of the patient and the agreement of the Ethics Committee of the Emergency Cardiovascular Diseases and Heart Transplantation Institute of Targu Mures, Romania.

Case presentation

A 43-year-old previously healthy patient presented in our Clinic of Cardiology for a routine check-up. He declared that his father had hypertension. No other cardiac or congenital disorders were reported.

The clinical exam revealed normosthenic constitution and pale skin, without any specific disorders. The cardiovascular examination showed rhythmic cardiac sounds, heart rate 95 beats per minute (bpm), third degree systolic murmur at the apex, normal blood pressure, and normal peripheral pulses. The ECG was normal, with sinus rhythm and heart rate (HR) at 95 bpm.

The 2D echocardiography showed an increased end-systolic left ventricle diameter. The diameter of left atrium in end-systole, which was measured in long axis view, from the posterior aortic wall to the posterior left atrial wall in a plane parallel to the mitral annulus was 35mm (normal values < 40 mm) [5]. The end-systolic diameter of left ventricle, measured in long axis view distal to the mitral leaflets' tips perpendicular to the long axis of the left ventricle, was 48 mm (normal value: 25.0–39.8mm in men)

* Correspondence to: Carmen Opris
E-mail: carmenchincisan@yahoo.com

[5]. The ejection fraction of the left ventricle was of 60%. The anterior leaflet of the mitral valve was normal. The posterior leaflet of the mitral valve showed flail of the P2 scallop, with severe mitral regurgitation. Eccentric regurgitation jet toward the interatrial septum was associated. The tricuspid valve had mild regurgitation, while the aortic and pulmonary valves did not present morphological or functional abnormalities. The transesophageal echocardiography confirmed flail of the posterior leaflet of the mitral valve, with chordal rupture at the P2 level (Figure 1).

Based on the echocardiographic-mentioned abnormalities, we transferred the patient to the Cardiovascular Surgery Department. The interdisciplinary team took the decision of surgical intervention according to internal protocols and the European Society of Cardiology (ESC) guidelines [1]. Mitral valve repair was performed under general anesthesia, with cardiopulmonary by-pass and pre- and post-surgery echocardiographic control. The stepwise complex mitral valve repair consisted of quadrangular resection, sliding of P1-P3 leaflets, suture of P2 leaflet and

mitral annuloplasty with a 34 mm prosthesis ring (Figure 2). Intraoperatively, injection of saline solution was necessary to test the competency of the mitral valve.

The postoperative transesophageal echocardiography showed mild mitral regurgitation, a coaptation line of 7 mm and good ventricular function (Figure 1).

The histological examination of the quadrangular fragment, which was resected from the posterior mitral leaflet, showed expansion and advanced myxomatous degeneration of the spongiosa layer, which was stained blue with PAS-Alcian. Secondary myxomatous involvement of the fibrosa did not associated modifications of the atrialis layer. Minimal fibrosis of the fibrosa layer, without significant destruction, was emphasized in red with Van Gieson stain (Figure 3).

After one month, the patient came for a check-up. The echocardiography showed no modifications of the ventricular function parameters, with only mild mitral regurgitation. No other complications were reported at the three-month follow-up.

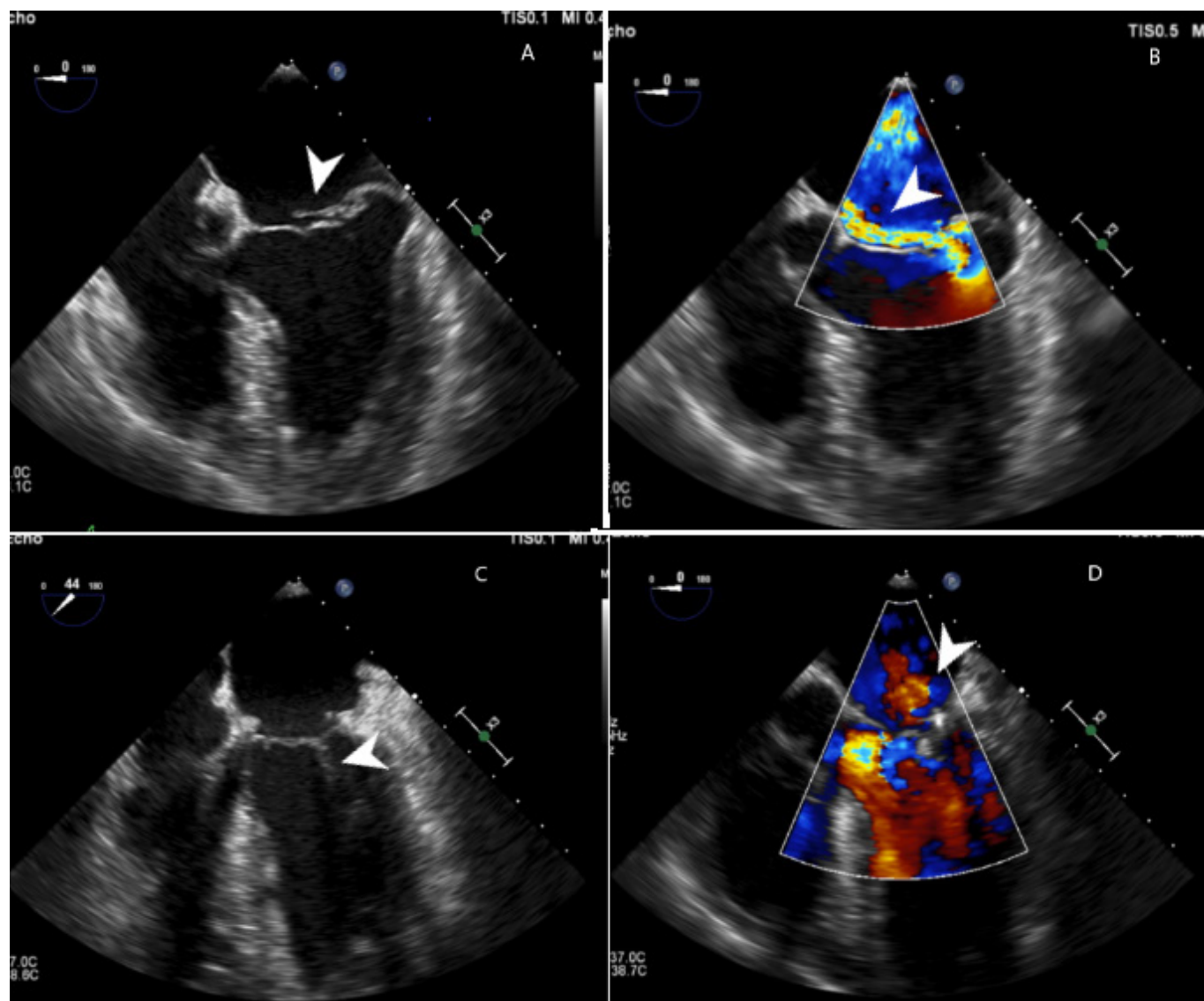


Fig. 1. Transesophageal echocardiography. A: Preoperative evaluation shows fail of the posterior leaflet of the mitral valve with a significant coaptation deficit; B: Preoperative color Doppler reveals severe, eccentric regurgitation jet oriented towards the interatrial septum; C: Postoperative examination shows mitral valve coaptation line; D Postoperative color Doppler shows a mild mitral regurgitation

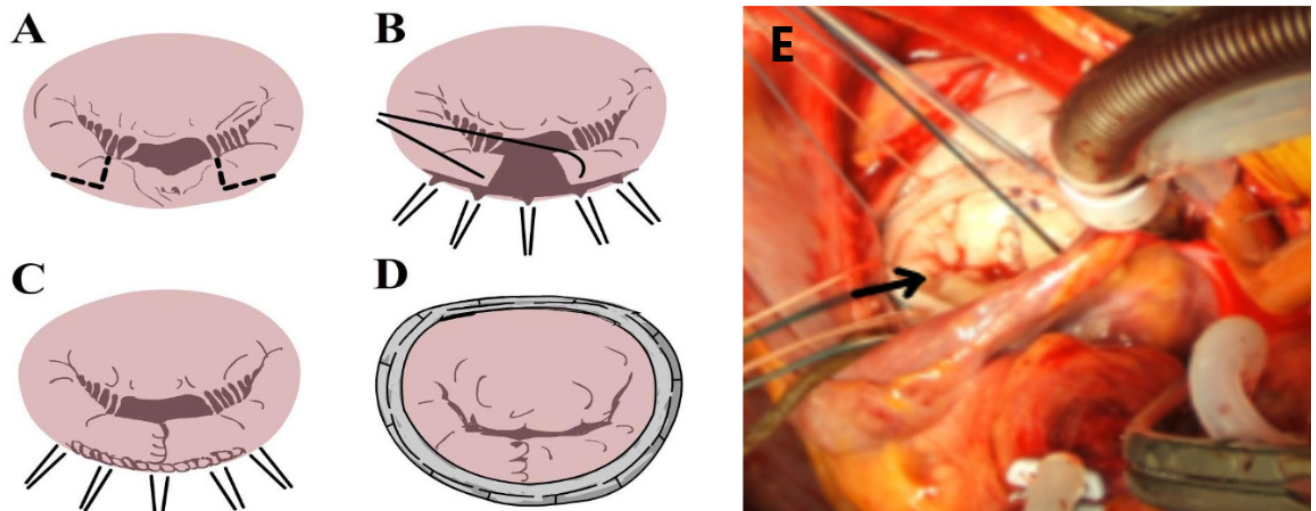


Fig. 2. The stepwise mitral valve repair-sliding technique. A: Quadranglar resection of the P2 prolapsed tissue; B: Sliding of the posterior mitral valve left tissue (P1 and P3); C: Re-anastomosis; D: Annuloplasty with a prosthesis ring; E: Intraoperative gross view, after the mitral valve repair, shows the mitral ring and suture visible at P2 level (arrow), with good coaptation of the mitral cusps

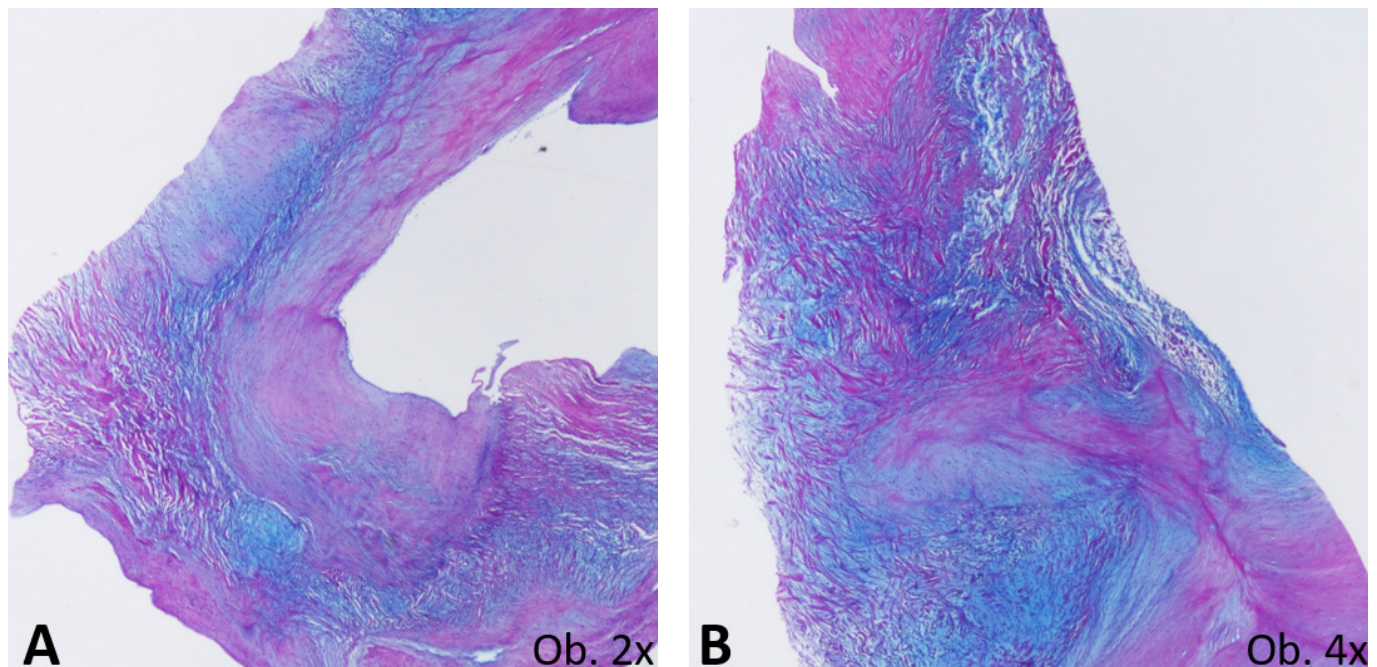


Fig. 3. Histological examination of the mitral valve shows a severe myxomatous degeneration of both spongiosa and fibrosa layers of the mitral valve, which are colored in blue with PAS-Alcian Blue histochemical staining method

Discussion

In the general population, the incidence of myxomatous degeneration of the mitral valve (estimated with echocardiography) is approximately 1-4% [2,3]. In young people, females are more frequently affected and males are more frequently asymptomatic [2]. In the case reported here, the young male had a routine check-up and did not report any specific symptoms. The routine check-up was decided at a young age, due to partially controlled hypertension of his father. The functional and morphological disorders were incidentally identified with echocardiography. The diagnosis of myxomatous degeneration was established by histological examination.

In asymptomatic patients there is controversy about the timing of surgery. According to the ESC guideline (2017), our case belonged to the IIa class recommendation, level of

evidence C [1]. In such cases, which are asymptomatic but associate severe mitral regurgitation caused by flail leaflet, valvular replacement or repair should be considered [1]. Although the recommendation varies from medical to surgical treatment, mitral valve repair is the first choice when possible [1,3,6]. The second option and the commonest one is replacement of the mitral valve [7,8].

Without surgery, the incidence of cardiac events (heart failure and new atrial fibrillation) in patients with severe mitral regurgitation but no symptoms is $33\pm 3\%$ [1]. The 5-year mortality rate is $14\pm 3\%$ [1]. It is higher in patients with severe organic mitral regurgitation, under close medical management, even with a tight follow-up [9].

After mitral valve repair, quality of life is improved and overall survival is prolonged [6]. After mitral valve replacement, complications include valve thrombosis, endocardi-

tis, malfunction and also side effects of the anticoagulant therapy [7]. However, only 40-50% of cases are treated by mitral valve reconstruction [7,8], such as in the case presented in this paper.

As regarding the stepwise valvular reconstruction, Carpentier described three principles for a good mitral valve reconstruction, which are still available [8]. It is about obtaining the longest surface of the leaflet coaptation (about 5-8 mm), followed by the full leaflet motion and an anuloplasty of the dilated mitral ring [10,11].

The most common method is the resection of abnormal valvular tissue. The main aim is to obtain a leaflet which has the closest shape to the native valve. Isolated prolapse of P2 may be treated by a quadrangular or triangular leaflet resection.

The intraoperatively 2D and 3D echocardiography are useful for a proper appreciation of the severity of the mitral regurgitation, assessment of the anatomy of the mitral valve and the mechanism of the mitral valve dysfunction [11]. They can be used to measure the mitral ring and the length of the leaflets and to evaluate the ventricular activity [11]. After surgery, echocardiography is necessary to appreciate the remnant grade of mitral regurgitation, the length of coaptation, the function of the ventricles and the presence of air in the heart cavities [11].

In asymptomatic young patients, such as in the presented case, successful repair of the mitral valve plays an important role in avoiding complications, such as the development of heart failure, dilated heart cavities, endocarditis, rupture of the chordae tendineae, arrhythmias, stroke and sudden cardiac death [2].

Conclusions

In asymptomatic patients with myxomatous degeneration of the mitral valve, predicting the right time for surgery is a difficult transdisciplinary decision. For patients with severe regurgitation, due to rupture of the myxomatous leaflet, the valve reconstruction is the therapy of choice. Histopathological evaluation is necessary to complete the echocardiographic assessment. Screening of the first-degree relatives of patients with histologically-proved myxomatous degeneration might help identification of cases with mitral prolapse in early stages.

Authors' contribution

Opris C performed the clinical investigations, as cardiologist, and drafted the manuscript; Suciu H participated at the clinical and surgical management of the case; Satala C participated at histological evaluation; Banceu C performed the patient's follow-up and search for literature data; Opris C performed the surgical intervention; Stoica A participated at the clinical and surgical management of the case; Capilna T contributed to search for literature data; Gurzu S contributed to manuscript drafting and allowed the final version of the paper. All authors approved the final version of the paper. Opris C and Satala C have equal contribution to the paper.

Conflicts of interest

None to declare.

References

1. Baumgartner H, Falk V, Bax JJ, et al. ESC Scientific Document Group. 2017 ESC/EACTS Guidelines for the management of valvular heart disease. *Eur Heart J* 2017;38:2739-2791.
2. Neto FL, Marques LC, Aiello VD. Myxomatous degeneration of the mitral valve. *Autops Case Rep* 2018;8:e2018058.
3. Guo Y, Song C, Wu X, et al. Comparison of outcomes of mitral valve repair for leaflet prolapse with advanced versus mild/moderate myxomatous degeneration. *Int Heart J* 2018;59:1288-1295.
4. Flack JM, Kvasnicka JH, Gardin JM, Gidding SS, Manolio TA, Jacobs DR. Anthropometric and physiologic correlates of mitral valve prolapse in a bi-ethnic cohort of young adults: the CARDIA study. *Am Heart J*. 1999;138:486-492.
5. Lang R, Badano PL, Mor-Avi V, et al. Recommendations for Cardiac Chamber Quantification by Echocardiography in Adults: An Update from the American Society of Echocardiography and the European Association of Cardiovascular Imaging. *J Am Soc Echocardiogr*. 2015;28:1-39.
6. Kang DH, Kim JH, Rim JH, et al. Comparison of early surgery versus conventional treatment in asymptomatic severe mitral regurgitation. *Circulation* 2009;119:797-804.
7. lung B, Baron G, Butchart EG, et al. A prospective survey of patients with valvular heart disease in Europe: The Euro Heart Survey on Valvular Heart Disease. *Eur Heart J* 2003;24:1231-1243.
8. Alreshidan M, Herron RD, Wei LM, et al. Surgical Techniques for Mitral Valve Repair: A Pathoanatomic Grading System. *Semin Cardiothorac Vasc Anesth* 2019;23:20-25.
9. Avierinos JF, Tribouilloy C, Grigioni F, et al. Impact of ageing on presentation and outcome of mitral regurgitation due to flail leaflet: a multicenter international study. *European Heart Journal* 2013; 34:2600-2609.
10. Carpentier A. La valvuloplastie reconstitutive - une nouvelle technique de valvuloplastie mitrale. *Presse Med* 1969;77:251-253.
11. Guo Y, He Y, Zhang Y, et al. Assessment of the mitral valve coaptation zone with 2D and 3D transesophageal echocardiography before and after mitral valve repair. *J Thorac Dis* 2018;10:283-290.