

CASE REPORT

# Ovarian Endometriosis and Malignant Transformation in Clear Cell Carcinoma

Ioana Maria Maier<sup>1\*</sup>, Adrian Cornel Maier<sup>2</sup>

1. Doctoral school, George Emil Palade University of Medicine, Pharmacy, Science, and Technology of Targu Mures, Romania

2. Department of Urology, Faculty of Medicine, University "Dunarea de Jos" Galati, Romania

Atypical endometriosis is considered to be precursors for malignancy. Coexistence of atypical endometriosis and ovarian neoplasm has been found in some studies. We describe the case of a 48-year old women diagnosed with clear cell carcinoma of ovary. The review of histological slide confirms the presence of benign endometriosis in both ovaries, the atypical endometriosis and clear cell carcinoma in the right ovary and the presence of uterine leiomyoma.

**Keywords:** endometriosis, atypical endometriosis, clear cell carcinoma

Received 8 July 2020 / Accepted 2 September 2020

## Introduction

Endometriosis affects 5-15 % women of childbearing age, and is defined by the presence of endometrial glands and stroma in other location than endometrium [1].

It has been estimated that 0.5-1% of ovarian endometriosis can get complicated with the appearance of neoplasia [2].

Clear cell carcinoma (CCC) is a type of ovarian neoplasm that is most often associated with ovarian endometriosis. CCC represents 10% of ovarian carcinomas being most frequent in Japan the age of onset is approximately 55 years [3].

## Case presentation

A 48-year-old woman was referred to Galati County Hospital for routine gynecological examination in May 2016. Ultrasound examinations revealed one voluminous mass tumor in the pelvic region; subsequently the patient is hospitalized in order to conduct additional investigations in the Clinic of Gynecology - following the investigations carried out: clinical examination, laboratory and imagistic confirm the presence of a tumor localized on the right ovary.

At admission, the results of laboratory were: leukocytes: 7500/ $\mu$ l, with 65 % PMN, 24% lymphocytes and 11% monocytes. Transaminases values were 38 UI for GOT and 29 UI for GPT. The level of CA125 marker for ovarian tumors was normal.

Computer tomography revealed the presence of one cystic tumor mass that has 6 cm dimension with adhesion of this mass on the sigmoidian wall, and on the uterine level the presence of solid mass that it's possible to be uterine leiomyoma. The patient underwent surgery, which included median laparotomy followed by total hysterectomy, bilateral salpingo-oophorectomy and tactical omentectomy.

Pathological exam revealed: macroscopy solid tumor with the size of 8x6x3 cm, compound of solid form of about 2 cm; microscopic examination highlighted the presence of structures such as: tubulocystic, papillary and solid patterns with necrosis in some areas.

The microscopical examination of the solid pattern shows areas composed of sheets of polyhedral cells, separated by delicate septa (Figure 1).

The cytoplasm is clear, rich in glycogen, separated by stroma. Lymphocytes are present in small number.

The tubulocystic pattern contains cells are arranged in one single layer and that contains eosinophilic secretions in lumen and intracytoplasmic secretions in some cells (Figure 2). The nuclei are large and hyperchromatic. The papillae are small and uniform.

Many endometrial glandular structures, some dilated, with endometrial stroma characteristic of endometriosis are present near the microscopical structures that are specific for the CCC in right ovary (Figure 3).

Of note, the transition between benign glandular structures of endometriosis to the atypical endometriosis is

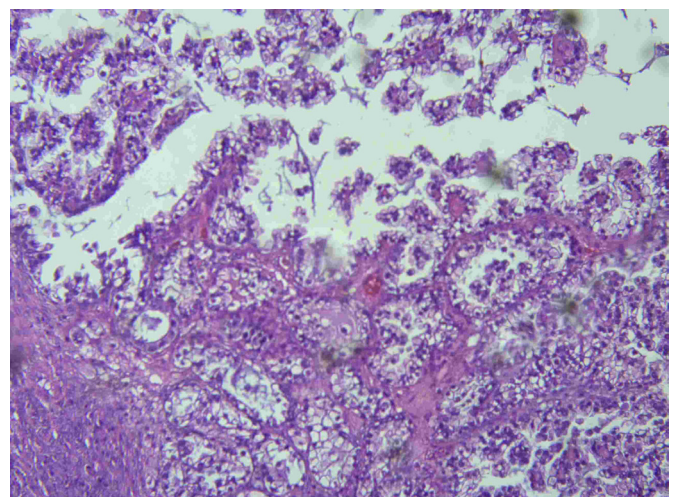


Fig. 1. Clear cell carcinoma -solid sheets with cells that presents clear cell cytoplasm in the bottom of the page

\* Correspondence to: Ioana Maria Maier  
E-mail: mioanamaier@gmail.com

characterized by eosinophilic cytoplasm, large nuclei and cellular pleomorphism, but also the transition between atypical endometriosis to the CCC (Figure 4).

Histopathologic exam of left ovary highlighted the presence of endometriosis foci represented by glands that resemble to those of the endometrium, some with cystic dilatation without atypia and surrounded by endometrial stroma.

The macroscopic examination of uterus revealed one round and fasciculate formation about 2 cm in size, intramural, white color and are well circumscribed, non-encapsulated, and have a bulging, firm. Microscopic exam revealed the specific appearance of a leiomyoma represented by cells with indistinct borders, eosinophilic fibrillary cytoplasm and cigar-shaped nuclei with small nucleoli disposed in fascicles specific for leiomyoma.

The presence of structures specific to endometriosis, atypical endometriosis, and neoplasia suggests the evolution of endometriosis to the clear cell carcinoma.

## Discussion

Sampson (1952) was the first who had described this transformation from endometriosis to the ovarian neoplasm. He had proposed three criteria to follow: the first is the presence of endometriosis foci and ovarian tumor in the same localization relatively close, the presence of endometrial stroma that surrounded endometrial glands, and a third criteria exclusion of primary tumor with other location. Later in 1953, Scott added the fourth criteria related to malign transformation of endometriosis [4].

Although this approach introduced by Scott represents one defining criteria in terms of neoplasm evolution from endometriosis, by highlighting one clear transition due to atypical endometriosis which is considered by some authors preneoplastic lesion, this criterion was identified in a small number of studies.

The presence of atypical endometriosis is considered an intermediary lesion between classic endometriosis and CCC [5].

This transformation was analyzed by La Grenade and Silverberg in 1988 when they were the first who presented a number of cases of ovarian tumors highlighting atypical endometriosis [6].

It has been estimated that the risk of malignancy is about 1% in cases with ovarian endometriosis [7].

Usually the atypia can be mild, but sometimes can be severe with unifocal, multifocal or diffuse foci [8]. It is known the fact that most frequent tumors which can appear as a results of malignisation ovarian endometriosis are CCC followed by endometrioid carcinoma and seromucinous carcinoma [9].

Several studies prove the association between endometriosis and ovarian carcinoma. Prevalence of endometriosis in ovarian carcinoma is between 4.2- 29.1% in literature [10].

In most cases with ovarian tumors the CA 125 marker presents higher levels, usually up to 200 U/ml which is

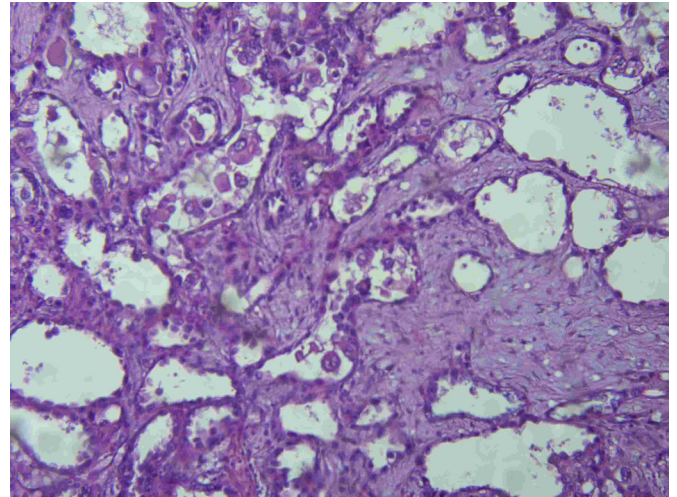


Fig. 2. Clear cell carcinoma with tubulocystic pattern that contain glands, some dilated, lined by a single layer of cells.

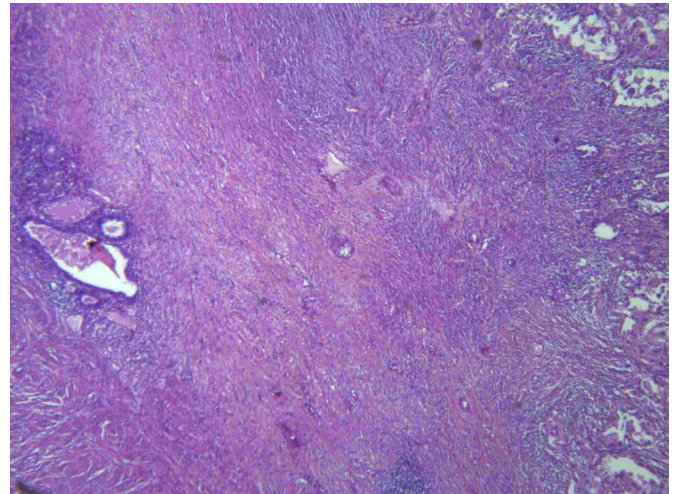


Fig. 3. The presence of both endometriosis (foci of endometriosis in left field) and clear cell carcinoma (right field)

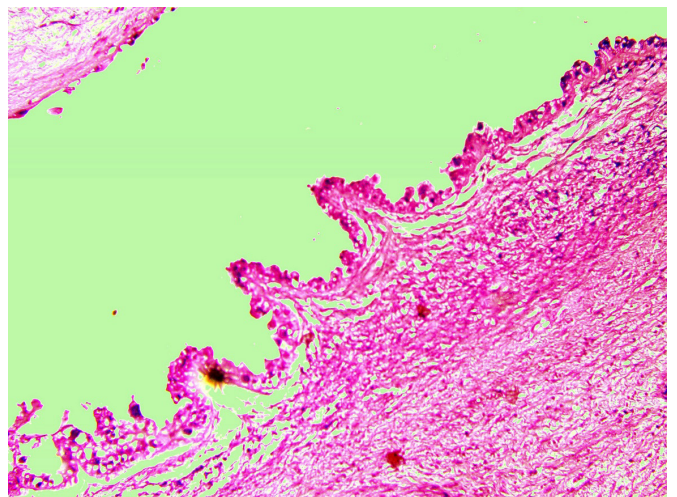


Fig. 4. The transition from atypical endometriosis to clear cell carcinoma

the specific marker for ovarian carcinoma. The present case showed normal level of CA-125 [11].

Van Gorp classifies the ovarian tumors associated with endometriosis in three groups: A, B and C. In the A group, the transition between endometriosis, atypical en-



dometriosis and ovarian carcinoma is obvious; in group B, endometriosis and ovarian endometriosis coexist, without any transition and in the group C the ovarian tumor and endometriosis is in other location in the pelvis. According to this classification the present case is included in A category [12].

Czernobilsky and Morris reported a percentage of 3.6% of endometriosis with atypia and without highlighting the neoplasia [13], Fukunaga et al. reported a frequent of 1,7% [8], Seidmann identified 32.3% [14], while Bayramoglu and Duzcan reported 5.8 % [15]. On the other hand, the incidence of atypical endometriosis with ovarian neoplasia associated being otherwise identified: 22.8 % by Ogawa et al, 14.7% by Fukunaga et al and 4.4 % by Oral et al [16].

In this case report, the age of patient of 48 years suggests the appearance of CCC at women at a younger age. This was identified in the study of Fukunaga et al. where CCC and endometrioid carcinoma associated with atypical endometriosis presented an average age between 46.2-48 [8]. Most patients diagnosed early with CCC presented an association with endometriosis; a study conducted in Japan revealed that 70% of patients with CCC which were associated with endometriosis [17,18].

This case highlights the possibility of transformation from the endometriosis foci to atypical endometriosis and malign transformation, which is supported by similar findings in other studies that we mentioned.

## Conclusion

Several studies revealed a high risk for development ovarian tumor in the patients diagnosed with endometriosis. In this pathology, an early diagnosis and treatment conduct to a good prognostic. The follow-up of patients with endometriosis needs a long and closer term run.

The long-term follow-up of this patient with endometriosis diagnosed at the clinic and ultrasound screening can prevent an evolution to malignisation, even if this was described in a small percentage by some authors.

## Author's contribution

M.I.M-Conceptualization, Investigation, Visualization, Writing – original draft, Writing – review & editing, Formal Analysis

M.A.C- Data curation, Writing – review & editing, Formal Analysis

## Bibliography

1. Matias-Guiu X, Stewart CJR. Endometriosis-associated ovarian neoplasia. *Pathology (Phila)*. 2018 Feb;50(2):190–204.
2. Wei J-J, William J, Bulun S. Endometriosis and Ovarian Cancer: A Review of Clinical, Pathologic, and Molecular Aspects. *Int J Gynecol Pathol*. 2011 Nov;30(6):553–68.
3. Mabuchi S, Sugiyama T, Kimura T. Clear cell carcinoma of the ovary: molecular insights and future therapeutic perspectives. *J Gynecol Oncol [Internet]*. 2016 Jan 4 [cited 2020 Jun 29];27(3). Available from: <https://doi.org/10.3802/jgo.2016.27.e31>
4. Scott RB. Malignant changes in endometriosis. *Obstet Gynecol*. 1953 Sep;2(3):283–9.
5. Vercellini P, Viganò P, Buggio L, Makieva S, Scarfone G, Cribiù FM, et al. Perimenopausal management of ovarian endometriosis and associated cancer risk: When is medical or surgical treatment indicated? *Best Pract Res Clin Obstet Gynaecol*. 2018 Aug;51:151–68.
6. LaGrenade A, Silverberg SG. Ovarian tumors associated with atypical endometriosis. *Hum Pathol*. 1988 Sep;19(9):1080–4.
7. Taniguchi F. New knowledge and insights about the malignant transformation of endometriosis. *J Obstet Gynaecol Res*. 2017 Jul;43(7):1093–100.
8. Fukunaga M, Nomura K, Ishikawa E, Ushigome S. Ovarian atypical endometriosis: its close association with malignant epithelial tumours. *Histopathology*. 1997 Mar;30(3):249–55.
9. McCluggage WG. Endometriosis-related pathology: a discussion of selected uncommon benign, premalignant and malignant lesions. *Histopathology*. 2020 Jan;76(1):76–92.
10. Akbarzadeh-Jahromi M, Shekarkhar G, Sari Aslani F, Azarpira N, Heidari Esfahani M, Momtahan M. Prevalence of Endometriosis in Malignant Epithelial Ovarian Tumor. *Arch Iran Med*. 2015 Dec;18(12):844–8.
11. Fadare O, Parkash V. Pathology of Endometrioid and Clear Cell Carcinoma of the Ovary. *Surg Pathol Clin*. 2019 Jun 1;12(2):529–64.
12. Niguez Sevilla I, Machado Linde F, Marín Sánchez M del P, Areñse JJ, Torroba A, Nieto Díaz A, et al. Prognostic importance of atypical endometriosis with architectural hyperplasia versus cytologic atypia in endometriosis-associated ovarian cancer. *J Gynecol Oncol [Internet]*. 2019 Apr 1 [cited 2020 May 3];30(4). Available from: <https://doi.org/10.3802/jgo.2019.30.e63>
13. Czernobilsky B, Morris WJ. A Histologic Study of Ovarian Endometriosis with Emphasis on Hyperplastic and Atypical Changes. *Obstet Gynecol*. 1979 Mar;53(3):318–23.
14. Jd S. Prognostic Importance of Hyperplasia and Atypia in Endometriosis [Internet]. *International journal of gynecological pathology : official journal of the International Society of Gynecological Pathologists*. 1996 [cited 2020 Jun 26]. Available from: <https://pubmed.ncbi.nlm.nih.gov/8852439/>
15. Bayramodlu H, Düzcan E. Atypical epithelial changes and mutant p53 gene expression in ovarian endometriosis. *Pathol Oncol Res*. 2001 Mar 1;7(1):33–8.
16. Oral E, Ilvan S, Tustas E, Korbeyli B, Bese T, Demirkiran F, et al. Prevalence of endometriosis in malignant epithelial ovary tumours. *Eur J Obstet Gynecol Reprod Biol*. 2003 Jul 1;109(1):97–101.
17. Aw K, Cv B, Wr H, Kd W. Ovarian Clear Cell Adenocarcinoma [Internet]. *Gynecologic oncology*. 1989 [cited 2020 Jun 25]. Available from: <https://pubmed.ncbi.nlm.nih.gov/2920955/>
18. Ogawa S, Kaku T, Amada S, Kobayashi H, Hirakawa T, Ariyoshi K, et al. Ovarian Endometriosis Associated with Ovarian Carcinoma: A Clinicopathological and Immunohistochemical Study. *Gynecol Oncol*. 2000 May 1;77(2):298–304.