

RESEARCH ARTICLE

Comparative analysis of mandibular changes after orthodontic treatment with and without extraction of four premolars: A digital cephalometric study

Anithab Alex, Keerthan Shashidhar, Kuttappa M N*, Krishna U S Nayak, Sai Kalyan Menta, Anushree A

Department of Orthodontics and Dentofacial Orthopedics, A B Shetty Memorial Institute of Dental Sciences; NITTE Deemed to be University, Mangalore, Karnataka, India

Objective: To compare and evaluate the cephalometric hard and soft tissue changes of mandible after orthodontic treatment with and without extraction of four first premolar. **Methodology:** 60 individuals with Class I skeletal pattern were selected as per inclusion criteria. They were divided into two groups: 30 in the extraction group and 30 in the non-extraction group. Each group consists of 15 males and 15 females. Pre-treatment and post-treatment lateral cephalograms of the selected subjects were obtained, analysed and compared to assess the changes might have occurred. Descriptive statistics of the explanatory and outcome variables were calculated by mean and standard deviation for quantitative variables. Paired t test was applied to check the statistical difference of pre-treatment and post-treatment cephalometric parameters within the group (Extraction and non-extraction). Unpaired t test was used to check the statistical difference between extraction and non-extraction groups. The level of significance is set at 5%. **Results:** B point moved backward with lower incisor retraction. N-A-Pog shows a statistically significant decrease in the extraction group ($P=0.003$). B-NP shows a statistically significant decrease in extraction group ($P=0.001$). N- A'-Pog' shows a statistically significant increase in non-extraction group ($P=0.046$). Soft tissue thickness in chin increases in extraction group and decreases in non-extraction group. **Conclusion:** The results indicate that premolar extraction will have a flattening effect on the midface. With proper diagnosis and treatment planning, premolar extractions have high potential to improve the facial profile.

Keywords: corrective orthodontics, premolar, chin, tooth extraction, mandible

Received 7 April 2022 / Accepted 2 June 2022

Introduction

A beautiful face is centered on symmetry and balance. A well-defined chin and jawline are critical to this harmony. Facial harmony with a stable, functional occlusion is considered to be an important objective of orthodontic treatment. The diagnosis and treatment planning of dentofacial problems focus primarily on the soft tissue profile rather than dentoskeletal structures, which is termed the 'paradigm shift.' It has emerged in the field of orthodontics and orthognathic surgery [1].

A harmonious soft and hard tissue of the chin is essential for an attractive lower one-third and overall facial beauty. An important aim of orthodontic treatment is to achieve a harmonious soft tissue profile. But it is difficult to achieve it because the soft tissue covering the teeth and bones are variable in their thickness. These variations are not only due to an imbalance of the dental and skeletal structures but also due to variations in the thickness and tone of the soft tissues [2].

Premolar extraction in orthodontic treatment has been a matter of debate for the last 100 years. Several studies documented that premolar extraction is commonly done as part of orthodontic treatment. Located between the anterior and posterior teeth, premolar extractions serve as a convenient method of correction of crowding and forwardly placed incisors [3].

The adverse effects hypothesized with extraction treatment plan are dish in profile, increased width of the buccal corridor, narrow dental arches, etc while non-extraction was hypothesized with poor stability and protrusive profile in borderline cases [4].

Many studies[5-7] have been done to analyse the effects of incisor movement and soft tissue profile changes. But fewer studies have been done on the chin changes after premolar extraction. The use of skeletal, dental, and soft-tissue cephalometric measurements is very valuable as a basic tool for the diagnosis, treatment plan, and evaluation of orthodontic treatment. The study aims to analyse and compare the hard and soft tissue changes in the mandible with and without extraction orthodontic treatment protocol.

Materials and methods

This retrospective study involves the identification and collection of 120 digital lateral cephalograms from the archives of the orthodontic department of the dental college. With 95% confidence level and 80% power, the minimum sample size required came upto 30 in each group.

Prior to the study, institutional ethical clearance was obtained : (ABSM/EC37/2019) The study was then carried out using pre-treatment and post-treatment lateral cephalograms of 60 individuals. These cephalograms were made using planmeca pro-max 2D (manufactured by Planmeca Oy). The exposure parameters for the digital cephalograms were standardized at 66kb, 5mA and 18.7 seconds. All cephalograms were taken in the natural head position.

* Correspondence to: Kuttappa M N
E-mail: kuttappa27@gmail.com

They were then divided into 30 in the extraction group and 30 in the non-extraction group. Each group consisting of 15 males and 15 females.

Eight Cephalometric Parameters were measured for each cephalogram using the digital cephalometric software, NEMOCEPH v.12 (Figure 1, 2)

1. Angle of Convexity – Formed by the intersection of line joining N - Point A and point A – Pogonion
2. B-NP – Is the linear distance of Point B from a Line Drawn Perpendicular from N Point
3. Pog – NP - Is the linear distance of Pogonion from a Line Drawn Perpendicular from N Point
4. SNB - The Angle formed by joining point S, N and B

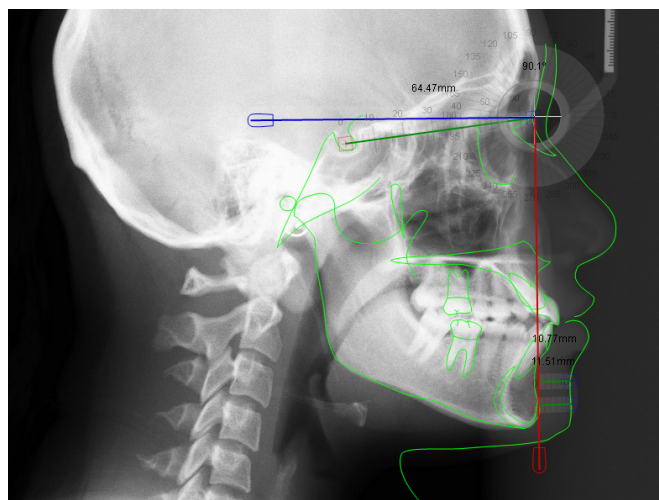


Fig. 1. Cephalometric Tracing on Nemoceph Software

Soft tissue parameters are presented in Figure 3.

1. SN-Pog' – The angle formed by Joining the points S N and Soft tissue pogonion (P')
2. Angle of convexity for soft tissue - Formed by the intersection of line joining N – Soft Tissue point A (A') and Soft Tissue point A (A')– Soft tissue Pogonion (P')
3. B'-NP - Is the linear distance of Soft Tissue Point B (B') from a Line Drawn Perpendicular from N Point
4. Pog'-NP - Is the linear distance of Soft Tissue Pog (Pog') from a Line Drawn Perpendicular from N Point.

Cephalometric records of patients with Class I skeletal malocclusion with bimaxillary protrusion were included in the study. Adult patients (20-35 years) who were treated with fixed straight wire appliances (0.022-inch; MBT prescription) and had an average mandibular plane angle (Frankforts Mandibular Plane Angle – 25 ± 5 degrees) were included in the study. The selected sample's pre-treatment and post-treatment radiographs were then traced.

Individuals with syndromes and facial deformities, Class II and class III skeletal malocclusion, inter incisal angle above 120° , presence of gross facial asymmetry, individuals with congenital anomalies and missing teeth (except third molars) were excluded from the study. Patients treated with temporary anchorage devices and patients with malocclusion in vertical direction/ history of trauma were also excluded from this study.

Statistical analysis

Paired t test was applied to check the statistical difference of pre-treatment and post-treatment cephalometric parameters within the group (Extraction and non-extraction). Unpaired t test was used to check the statistical difference between extraction and non-extraction groups. The level of significance was set at 5%. Data was compared and subjected to statistical analysis using Version 20 of the statistical package for social sciences (SPSS INC, Chicago, Illinois, USA).

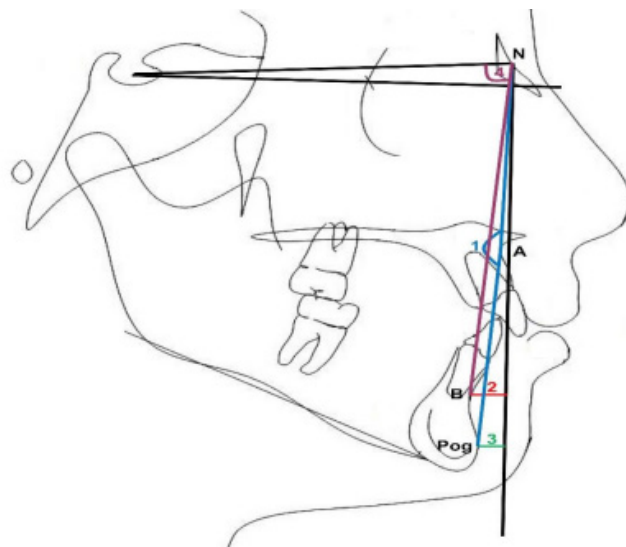


Fig. 2. Cephalometric hard tissue measurement; 1: Angle of Convexity 2: B-NP 3: Pog-NP 4: SNB

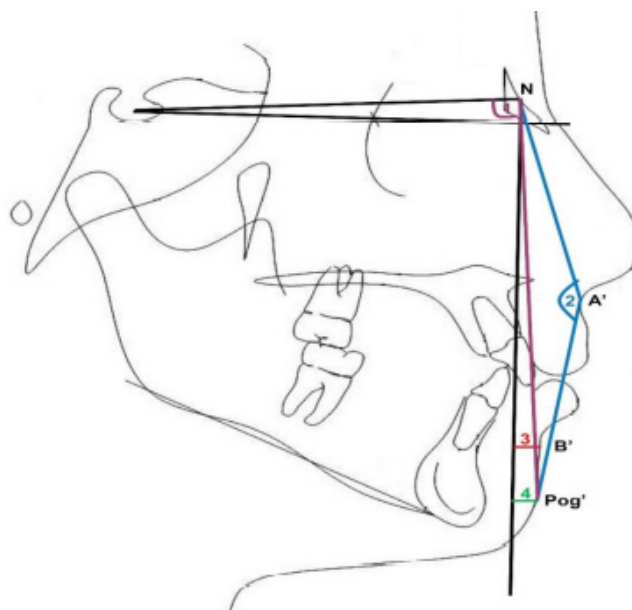


Fig. 3. Cephalometric soft tissue measurements; 1: SN-Pog', 2: Angle of convexity for soft tissue, 3: B'-NP, 4: Pog'-NP

Results

The present study was undertaken with the aim of comparing and evaluating the cephalometric hard and soft tissue changes in mandible after orthodontic treatment with and without extraction of four first premolars.

Table 1 shows the comparison of the pre and post cephalometric parameters within the group (Extraction and Non-extraction)

Table 2 shows the comparison of the cephalometric parameters between the groups (extraction and non-extraction) at different time intervals (Pre and Post Treatment)

The mean angular changes in B point represented by the SNB angle were relatively the same in both groups of extraction and non-extraction. SNB values were slightly higher in pre-treatment values of non-extraction group (81.57 ± 3.5) as compared to post-treatment values (81.17 ± 3.31). Similarly, SNB values were slightly higher in pre-treatment values of extraction group (80.93 ± 3.54) as compared to post treatment values (80.63 ± 3.45). Paired t-test showed no statistically significant difference in both non-extraction ($P=0.15$) and extraction group ($P=0.107$). Unpaired t-test showed no statistically significant difference in both pre ($p=0.48$) and post ($p=0.54$) time intervals between non-extraction and extraction group.

The angle of convexity represented by N-A-Pog were slightly higher in the pre-treatment value of non-extraction

group (6 ± 3.78) as compared to post treatment values (5.30 ± 3.51). In extraction group Pre-treatment N-A-Pog values were slightly higher (7.20 ± 3.12) as compared to post treatment values (6.17 ± 2.96). Paired t test showed no statistically significance in non-extraction group ($p=0.12$) and in extraction group showed statistically significant difference. ($P=0.003$). Unpaired t test showed no statistically significant difference in both pre ($p=0.18$) and post ($p=0.3$) time intervals between non-extraction and extraction group.

The mean changes of point B represented by B-NP were higher in the pre-treatment non-extraction group [-1.88 ± 5.85] compared with post-treatment values [-2.03 ± 5.99]. In extraction group, the mean value is higher in pre-treatment [-2.43 ± 4.91] compared to post-treatment value [-3.79 ± 4.63]. The paired t test showed no statistically significant difference in non-extraction [$P=0.84$] and statistically significant difference in extraction group [$P=0.001$]. Unpaired t test showed no statistically significant difference in both pre ($p=0.69$) and post ($p=0.20$) time intervals between non-extraction and extraction group.

The mean changes in the pogonion represented with Pog-NP were higher in the post-treatment non-extraction group [-0.57 ± 6.28] compared with pre-treatment values [-0.83 ± 6.29]. In extraction group the mean value is higher in post treatment group [-2.27 ± 5.90] compared to the pre-

Table 1. Comparison Of The Pre And Post Cephalometric Parameters Within The Groups (Extraction And Non-Extraction) Using Paired Sample t-test (*=significant)

Parameters	Groups	Time intervals	N	Minimum	Maximum	Mean	S.D	Mean diff	p value
SNB (Degrees)	Non-extraction	Pre	30	73.0	89.0	81.57	3.50	0.4	0.15
		Post	30	73.0	87.0	81.17	3.31		
	Extraction	Pre	30	73.0	86.0	80.93	3.54	0.3	0.107
		Post	30	73.0	86.0	80.63	3.45		
N-A-Pg (Degrees)	Non-extraction	Pre	30	1.0	12.0	6.00	3.78	0.7	0.12
		Post	30	1.0	11.0	5.30	3.51		
	Extraction	Pre	30	1.0	12.0	7.20	3.12	1.03	0.003*
		Post	30	1.0	12.0	6.17	2.96		
B-NP (mm)	Non-extraction	Pre	30	-16.24	10.40	-1.88	5.85	0.15	0.84
		Post	30	-12.74	11.54	-2.03	5.99		
	Extraction	Pre	30	-11.68	6.14	-2.43	4.91	1.36	0.001*
		Post	30	-11.94	4.20	-3.79	4.63		
Pog-NP (mm)	Non-extraction	Pre	30	-16.92	12.06	-0.83	6.29	-0.25	0.79
		Post	30	-13.22	14.01	-0.57	6.28		
	Extraction	Pre	30	-14.10	7.04	-2.48	6.12	-0.204	0.75
		Post	30	-14.35	7.24	-2.27	5.90		
SN-Pog' (Degrees)	Non-extraction	Pre	30	79.0	96.0	88.00	3.80	0.16	0.69
		Post	30	80.0	99.0	87.83	3.74		
	Extraction	Pre	30	79.0	92.7	87.06	3.77	-0.57	0.16
		Post	30	81.0	94.0	87.63	3.69		
N-A'-Pg' (Degrees)	Non-extraction	Pre	30	6.0	25.0	14.83	4.90	-1.4	0.046*
		Post	30	7.0	29.0	16.30	5.48		
	Extraction	Pre	30	6.0	25.0	16.47	4.95	1.00	0.12
		Post	30	6.0	24.0	15.47	4.67		
B'-NP (mm)	Non-extraction	Pre	30	-3.20	21.51	9.03	5.64	-0.24	0.73
		Post	30	-1.23	25.10	9.27	5.52		
	Extraction	Pre	30	-5.93	17.89	8.36	6.38	-0.21	0.66
		Post	30	-4.10	18.10	8.58	5.94		
Pog'-NP (mm)	Non-extraction	Pre	30	-6.63	22.50	9.04	6.16	0.097	0.88
		Post	30	-5.29	26.94	8.95	6.66		
	Extraction	Pre	30	-7.05	18.43	7.46	6.43	-0.81	0.15
		Post	30	-5.19	17.75	8.28	6.30		

Table 2. Comparison Of The Cephalometric Parameters Between The Groups (Extraction And Non-Extraction) At Different Time Intervals (Pre and Post Treatment)Using Unpaired Sample t-test

Parameters	Time intervals	Groups	N	Minimum	Maximum	Mean	S.D	Mean diff	p-value
SNB (Degrees)	Pre	Non-extraction	30	73.0	89.0	81.57	3.50	0.63	0.48
		Extraction	30	73.0	86.0	80.93	3.54		
	Post	Non-extraction	30	73.0	87.0	81.17	3.31		
		Extraction	30	73.0	86.0	80.63	3.45		
N-A-Pg (Degrees)	Pre	Non-extraction	30	1.0	12.0	6.00	3.78	-1.2	0.18
		Extraction	30	1.0	12.0	7.20	3.12		
	Post	Non-extraction	30	1.0	11.0	5.30	3.51		
		Extraction	30	1.0	12.0	6.17	2.96		
B-NP (mm)	Pre	Non-extraction	30	-16.24	10.40	-1.87	5.85	0.55	0.69
		Extraction	30	-11.68	6.14	-2.43	4.91		
	Post	Non-extraction	30	-12.74	11.54	-2.03	5.99		
		Extraction	30	-11.94	4.20	-3.79	4.63		
Pog-NP (mm)	Pre	Non-extraction	30	-16.92	12.06	-0.83	6.29	1.65	0.3
		Extraction	30	-14.10	7.04	-2.48	6.12		
	Post	Non-extraction	30	-13.22	14.01	-0.57	6.28		
		Extraction	30	-14.35	7.24	-2.27	5.90		
SN-Pog' (Degrees)	Pre	Non-extraction	30	79.0	96.0	88.00	3.80	0.94	0.33
		Extraction	30	79.0	92.7	87.06	3.77		
	Post	Non-extraction	30	80.0	99.0	87.83	3.74		
		Extraction	30	81.0	94.0	87.63	3.69		
N-A'-Pg' (Degrees)	Pre	Non-extraction	30	6.0	25.0	14.83	4.90	-1.6	0.2
		Extraction	30	6.0	25.0	16.47	4.95		
	Post	Non-extraction	30	7.0	29.0	16.30	5.48		
		Extraction	30	6.0	24.0	15.47	4.67		
B'-NP (mm)	Pre	Non-extraction	30	-3.20	21.51	9.02	5.63	0.66	0.66
		Extraction	30	-5.93	17.89	8.35	6.37		
	Post	Non-extraction	30	-1.23	25.10	9.27	5.51		
		Extraction	30	-4.10	18.10	8.58	5.94		
Pog-NP (mm)	Pre	Non-extraction	30	-6.63	22.50	9.04	6.16	1.57	0.33
		Extraction	30	-7.05	18.43	7.46	6.43		
	Post	Non-extraction	30	-5.29	26.94	8.95	6.66		
		Extraction	30	-5.19	17.75	8.28	6.30		

treatment value of $[-2.48 \pm 6.12]$. The paired t test showed no statistically significant difference in both non-extraction $[P = 0.79]$ and extraction group $[P = 0.75]$. Unpaired t test showed no statistically significant difference in both pre $(p = 0.3)$ and post $(p = 0.28)$ time intervals between non-extraction and extraction group.

The mean changes in the pogonion [Pog] represented by SN-Pog in the non-extraction group, pre-treatment shows higher value $[88 \pm 3.80]$ compared with a post-treatment value $[87.83 \pm 3.74]$. In extraction group post treatment shows a higher value $[87.63 \pm 3.69]$ compared to pre-treatment value of $[87.06 \pm 3.77]$. Paired t test showed no statistically significant difference in both non-extraction $[P = 0.69]$ and extraction group $[P = 0.16]$. Unpaired t test showed no statistically significant difference in both pre $(p = 0.33)$ and post $(p = 0.83)$ time intervals between non-extraction and extraction group.

The mean soft tissue convexity represented by N-A'-Pog' in the non-extraction group, post-treatment shows a higher value $[16.30 \pm 5.48]$ compared to the pre-treatment value $[14.83 \pm 4.90]$. In extraction group, higher value is shown by pre-treatment group $[16.47 \pm 4.95]$ compared to the post-treatment value $[15.47 \pm 4.67]$. Paired t test showed statistically significant results in the non-extraction group

$[P = 0.046]$ compared to the extraction group $[P = 0.12]$. Unpaired t test showed no statistically significant difference in both pre $(p = 0.2)$ and post $(p = 0.52)$ time intervals between non-extraction and extraction group.

The mean changes in soft tissue point B represented by B'-NP in the non-extraction group, post-treatment shows higher value $[9.27 \pm 5.52]$ compared with pre-treatment value $[9.03 \pm 5.64]$. In extraction group, post-treatment shows higher value $[8.58 \pm 5.94]$ compared to pre-treatment value $[8.36 \pm 6.38]$. Paired t test showed no statistically significant results in non-extraction group $[P = 0.73]$ and in extraction group $[P = 0.66]$. Unpaired t test showed no statistically significant difference in both pre $(p = 0.66)$ and post $(p = 0.64)$ time intervals between non-extraction and extraction group.

The mean changes in the pogonion represented by Pog-NP in the non-extraction group, pre-treatment shows higher values $[9.04 \pm 6.16]$ compared to the post-treatment value $[8.95 \pm 6.66]$. In extraction group, post-treatment shows higher value $[8.28 \pm 6.30]$ compared with pre-treatment value $[7.46 \pm 6.43]$. Paired t test showed no statistically significant difference in both non-extraction $[P = 0.88]$ and extraction group $[P = 0.15]$. Unpaired t test showed no statistically significant difference in both pre $(p = 0.33)$ and

post($p=0.69$) time intervals between non-extraction and extraction group.

Discussion

Dento-facial problems have a negative impact on the patient's self-esteem. Various studies have been conducted on the dimensions of individual components of face and its impact on facial beauty. These components include lip profile [8], lip thickness [9], over jet [10], gingival contour [11] and anterior teeth alignment [12]. Premolar extraction and its impact on facial aesthetics is a controversial subject. Several studies prove that premolar extraction does not negatively influence the facial aesthetics [13] while others have proven otherwise. The present study aims to compare the hard and soft tissue changes in the mandible after orthodontic treatment with and without the extraction of all four first premolar. Standard cephalometry was used for the analysis of hard and soft tissue changes in the mandible of patients treated with and without premolar extraction.

The mean changes in point B represented by SNB angle in this study showed decreased value in the extraction group compared to non-extraction group but was statistically insignificant. Our study showed a reduction of 0.3 degrees in post-treatment value when compared with pre-treatment value. The decrease in SNB angle can be attributed to the retraction of point B associated with incisor retraction [14]. A study done by Erdinc et al. [15] showed that the extraction group shows a mean reduction of 0.31 degrees in post treatment value when compared to the pre-treatment value. Similar results were seen in our study. Non extraction group showed a mean increase of 0.3 degrees in post treatment value when compared to the pre-treatment value. In our study non-extraction group showed a mean reduction of 0.4 degrees in post treatment value when compared to the pre-treatment value. A study done by Shashidhar et al. [16] in skeletal class II malocclusion stated that the mean post treatment value of SNB showed a reduction of 0.65 degrees when compared with the pre-treatment value. The statistically significant decrease in the SNB angle indicated that there was a potential worsening of the patient's profile. The reason for decrease in SNB angle could be attributed to clockwise rotation of the mandible.

Skeletal convexity represented by N-A-Pog was decreased in both non-extraction group and extraction group in our study. The mean post treatment value of N-A-Pog shows a reduction of 1.03 degrees in the extraction group when compared to the pre-treatment values, and was statistically significant. Comparison of pre-treatment and post treatment values in non-extraction group showed a mean reduction of 0.7 degrees and showed no statistically significant difference. A study done by Faruk Ayhan Baciftci et al [17] showed that the skeletal convexity decreased after orthodontic correction. Another study done by Hosseinza-deh -Nik et al. [18] showed similar results. A decrease in

skeletal convexity showed that extraction treatment does bring about flattening of the midface.

The skeletal changes in Point B represented by B-NP showed decreased post-treatment value when compared with the pre-treatment value in both extraction and non-extraction group. Comparison of pre-treatment and post-treatment values in extraction group showed a mean difference of 1.36 mm and was statistically significant. Comparison of pre-treatment and post-treatment values in non-extraction group showed a mean difference of 0.7 mm and showed no statistically significant difference. Comparison of extraction and non-extraction group also showed no statistically significant difference. A Study done by J N Sharma [11] stated that skeletal Point B was retracted by 2.1 mm after orthodontic correction with four premolar extractions. The retraction of point B was attributed to the retraction of mandibular incisors and resultant remodeling of point B. Another study done by Rasha Al Abdwani et al [19] showed that for every 10° change in the mandibular incisor inclination there was an average change of 0.3 mm in point B in horizontal plane. Shashidhar et al [16] reported a mean increase of 1.1 mm in the post treatment extraction group when compared to the pre-treatment group which was statistically significant in their study.

The mean changes in the pogonion represented by Pog-NP showed a very minimal increase in the post-treatment value when compared with the pre-treatment value in extraction and non-extraction group. Non extraction group showed a slight increase with a mean value of -0.25 mm when compared to the pre-treatment value. Extraction group showed a slight increase in post treatment value compared to the pre-treatment value with a mean value of -0.204 mm. These values were of no statistical significance. Comparison of pre-treatment and post-treatment values of extraction and non-extraction group showed no statistically significant values. A study done by Hosseinza-deh -Nik et al. [18] showed an increased value in extraction group with a mean difference of 0.06 mm. This was similar to our results. An increased value in N-Pog shows that the facial profile does not worsen after orthodontic treatment with extraction. Contrary to our results, Shashidhar et al. [16] reported a mean increase of 1mm in the post-treatment group when compared to the pre-treatment group. The values were of statistical significance in their study. However, they assessed the effects of premolar extraction in Class 2 Div 1 subjects and that could be the reason why their results were contrary to ours.

The mean angular changes in the pogonion represented by SNPog² showed decreased value in the non-extraction group and slight increased value in the extraction group when compared between pre-treatment and post treatment values. Non extraction group showed a mean difference of 0.16mm in post-treatment value when compared with the pre-treatment value. Extraction group showed a mean difference of -0.57 mm in post treatment value when compared to the pre-treatment value. Comparison between

pre-treatment and post-treatment value of extraction and non-extraction group showed no statistically significant difference. Comparison of extraction and non-extraction group showed increased value in the non-extraction group. But these values were not statistically significant. A study done by Hosseinzadeh -Nik et al. [18] showed a decrease in post treatment value when compared with pre-treatment value in non-extraction and extraction group. In our study a slight increase of value in extraction group denotes that the facial profile was not significantly affected with extraction.

The mean changes in soft tissue convexity represented by N-A'-Pog' showed a decrease in post-treatment value when compared to the pre-treatment values in both extraction and non-extraction group, but was statistically significant only in the non-extraction group. Comparison between extraction and non-extraction group showed no statistically significant results. A study done by Benedito V Freitas et al [1] showed decrease in facial convexity angle in non-extraction group and slight increase in facial convexity in extraction group. Our study showed an increase in post treatment value in non-extraction group with a mean difference of -1.4 degree when compared to the pre-treatment value. This value was of statistical significance. The extraction group showed a decrease in value in post treatment group with a mean difference of 1 degree when compared to the pre-treatment value. This value was of no statistical significance. A study done by Dimitrios Konstantonis [20] evaluated borderline cases and shows a decreased value in post treatment extraction group with a mean difference of -0.52 degree when compared to the pre-treatment value. Non extraction group showed a slight decrease in value with a mean difference of -0.01 degree in post treatment group when compared to pre-treatment value. These values were of no statistical significance. In our study the soft tissue angle of convexity decreased in the extraction group which means extraction will bring about flattening of midface.

The mean soft tissue Point B changes represented by B'-NP showed slight increase in post treatment value when compared with pre-treatment value both in extraction and non-extraction group. The pre-treatment and post treatment B'-NP value in extraction group and non-extraction group showed no statistically significant results. Comparison between non-extraction and extraction group also showed no statistically significant results. A study done by Sharma [14] on A and B points in the hard and soft tissue after extraction of four first premolars and incisor retraction showed that Point B and Point B' were retracted by 2.1 mm and 1.2 mm respectively. Kachiwala et al [21] studied the facial soft tissue changes in female patients with extraction of premolars and stated that B' Point had no significant changes after treatment. Our study showed .22 mm of mean forward positioning of B' point in extraction group. The relaxation of mentalis muscle after orthodontic correction could be the cause of increased soft tissue thickness. RN Singh [2] evaluated the soft tissue

contour of chin pre and post treatment and after 5 years of completion of orthodontic treatment with extraction. The study concluded that the overall soft tissue thickness from B point to menton increased.

Mean soft tissue pogonion changes represented by Pog'-Np showed decrease in the value in non-extraction group and increase in the value in extraction group when compared between pre-treatment and post treatment values. There was no statistically significant difference between extraction and non-extraction group. A study done by AB Rathod et al [22] showed that in the extraction group there was increase of soft tissue chin. The study shows that maxillary incisor retraction tends to relieve the muscle tension around chin region and thereby increase the soft tissue thickness around the chin. It was similar to the findings in our study where in the decrease in the thickness in the non-extraction group denotes that the strain is further increased probably due to increased proclination of incisors.

Conclusions

The following conclusions can be made from this study

1. The mandible showed a reduction in the SNB angle when compared to the pre-treatment values which can be attributed to the remodeling of point B because of retraction of the incisors.
2. Skeletal convexity of the face represented by N-A-Pg showed a decrease in value in post treatment cases, confirming that extraction treatment does bring about flattening of the midface.
3. Point B moved backward with lower incisor retraction.
4. Soft tissue thickness of the chin increases in extraction group and decreases in non-extraction group.
5. Soft tissue point B shows a slight forward movement in both the extraction and non-extraction groups

Author Contributions

AA - Conceptualization, Data curation, Formal Analysis, Investigation, Methodology, Validation, Visualization, Writing – original draft, Writing – review & editing.

KS - Investigation, Methodology, Project administration, Resources, Writing – review & editing.

MN - Conceptualization, Data curation, Investigation, Methodology, Project administration, Resources, Software, Supervision, Validation, Visualization, Writing – original draft, Writing – review & editing.

US - Conceptualization, Data curation, Project administration, Supervision, Validation, Visualization, Writing – original draft, Writing – review & editing

SK - Data curation, Resources, Writing – original draft, Writing – review & editing.

AA - Investigation, Methodology, Resource, Writing – review & editing.

Conflict of interest

None to declare.

References

- Freitas BV, Rodrigues VP, Rodrigues MF, de Melo HVF, Dos Santos PCF. Soft tissue facial profile changes after orthodontic treatment with or without tooth extractions in Class I malocclusion patients: A comparative study. *J Oral Biol Craniofac Res*. 2019 Apr-Jun;9(2):172-176.
- Singh RN. Changes in the soft tissue chin after orthodontic treatment. *Am J Orthod Dentofacial Orthop*. 1990 Jul;98(1):41-6.
- James RD. A comparative study of facial profiles in extraction and nonextraction treatment. *Am J Orthod Dentofacial Orthop*. 1998 Sep;114(3):265-76.
- Yashwant V A, K R, Arumugam E. Comparative evaluation of soft tissue changes in Class I borderline patients treated with extraction and nonextraction modalities. *Dental Press J Orthod*. 2016 Jul-Aug;21(4):50-9.
- Baik W, Choi SH, Cha JY, Yu HS, Lee KJ. Comparison of soft tissue changes between incisor tipping and translation after premolar extraction. *Korean J Orthodontics*. 2022 Jan 25;52(1):42.
- Khare V, Niwlikar KB, Nathani RA, Sawant HR, Choudhari T, Vaishnavi AB. Changes in the Soft Tissue Chin Area by Retraction of Mandibular Orthodontic Incisors-A Retrospective Study. *Annals of the Romanian Society for Cell Biology*. 2021 Apr 23:8682-91.
- Al-Shakhs AS, Hashim HA. Soft Tissue Facial Profile Changes Associated with Incisors Retraction. *Eur J Clin Med*. 2021 Jun 30;2(3):92-9.
- Sadry S, Koru BE, Kayalar E. Analyzing the effects of tooth extraction on the lip in orthodontic treatment. *Journal of Stomatology, Oral and Maxillofacial Surgery*. 2022 Apr 20. In press. DOI: 10.1016/j.jormas.2022.04.004
- Kapoor S, Jaiswal AK, Chaudhary G, Kochhar A, Ryait JK, Singh C. Lip morphology changes after first premolar extractions in patients with bimaxillary protrusion in North Indian population-A pilot study. *International Journal of Orthodontic Rehabilitation*. 2021 Jan 1;12(1):13.
- Freitas KMS, Massaro C, Miranda F, de Freitas MR, Janson G, Garib D. Occlusal changes in orthodontically treated subjects 40 years after treatment and comparison with untreated control subjects. *Am J Orthod Dentofacial Orthop*. 2021 Nov;160(5):671-685.
- Ozeki Y, Ozaki H, Fushima K. Change in clinical crown height in adult patients treated by means of the multi-bracket appliance with extraction of four first premolars. *J Orthodontics*. 2021 Dec;48(4):371-82.
- Jung MH. Evaluation of the effects of malocclusion and orthodontic treatment on self-esteem in an adolescent population. *Am J Orthod Dentofacial Orthop*. 2010 Aug;138(2):160-6.
- Johnson DK, Smith RJ. Smile esthetics after orthodontic treatment with and without extraction of four first premolars. *Am J Orthod Dentofacial Orthop*. 1995 Aug;108(2):162-7.
- Sharma JN. Skeletal and soft tissue point A and B changes following orthodontic treatment of Nepalese Class I bimaxillary protrusive patients. *Angle Orthod*. 2010 Jan; 80(1):91-6.
- Erdinc AE, Nanda RS, Dandajena TC. Profile changes of patients treated with and without premolar extractions. *Am J Orthod Dentofacial Orthop*. 2007 Sep;132(3):324-31.
- Shashidhar K, Castelino C, Kuttappa M, et al. Skeletal Changes Seen in Nonsurgically Treated Patients with Skeletal Class II Malocclusion. *World J Dentistry*. 2021;12 (2):144-149
- Faruk Ayhan Basciftci, Tancan Uysal, Ahmet Buyukerkmen, Abdullah Demir. The Influence of Extraction Treatment on Holdaway Soft-Tissue Measurements. *Angle Orthod*. 2004;74:167-173.
- Hosseinzadeh-Nik T, Eftekhari A, Shahroudi AS, Kharrazifard MJ. Changes of the Mandible after Orthodontic Treatment with and without Extraction of Four Premolars. *J Dent (Tehran)*. 2016 Jun;13(3):199-206.
- Al-Abdwani R, Moles DR, Noar JH. Change of incisor inclination effects on points A and B. *Angle Orthod*. 2009 May;79(3):462-7.
- Konstantonis D. The impact of extraction vs nonextraction treatment on soft tissue changes in Class I borderline malocclusions. *Angle Orthod*. 2012 Mar;82(2):209-17.
- Kachiwala VA, Kalha AS, Machado G. Soft tissue changes associated with first premolar extractions in adult females. *Australian Orthod J*. 2009 May;25(1):24-9.
- Rathod AB, Araujo E, Vaden JL, Behrents RG, Oliver DR. Extraction vs no treatment: Long-term facial profile changes. *Am J Orthod Dentofacial Orthop*. 2015 May 1;147(5):596-603.