

RESEARCH ARTICLE

Herlant's Tetrachrome Staining, a Useful Tool for Pituitary Adenoma Diagnosis

Chinezu Laura¹, Trouillas Jacqueline², Loghin Andrada¹, Borda Angela¹

¹ Department of Histology, University of Medicine and Pharmacy, Tîrgu Mureş, Romania

² Hospices Civils de Lyon, INSERM U1028; CNRS UMR5292; Lyon Neuroscience Research Center, Neuro-oncology & Neuro-inflammation team, University Lyon 1, Lyon, France

Introduction: The morphologic diagnosis of pituitary adenomas (PA) is based on immunohistochemistry (IHC). In Romania, IHC diagnosis of PA is restricted, all of the specific antibodies being very expensive. A histochemical staining, Herlant's tetrachrome (HTCS), was described several years ago, but it was not widely used for diagnostic purposes because of technical difficulties. The aim of this paper is to bring into discussion this staining, to highlight its benefits, to improve the technical procedures and to establish a protocol, which combining both HTCS and IHC, facilitates the diagnosis of PA and, especially, substantially reduces the costs.

Methods: HTCS was performed using normal pituitary glands. The optimal time of staining and the optimal concentration of different solutions were established for each step of the staining.

Results: The improved technical procedure of HTCS is described. The staining features of all cellular types of the pituitary gland are depicted and illustrated: the chromophore cells, GH-secreting cells stained in orange, PRL-secreting cells in red-violet and ACTH-cells in dark blue, while chromophobe cells stained light blue. These staining features can be extrapolated to the diagnosis of PAs, as they consist of a proliferation of such cells.

Conclusion: HTCS's benefit is in functional PAs: it can identify GH, PRL, ACTH and TSH-adenomas, according to the cell type staining. A two-step diagnostic protocol is proposed, allowing the use of two, maximum three antibodies, instead of six: first step HTCS, and second step IHC.

Keywords: pituitary adenoma, Herlant's tetrachrome staining, immunohistochemistry

Received: 3 June 2013

Introduction

Pituitary adenomas (PA) are rare tumors, representing approximately 15% of intracranial tumors [1]. The diagnosis is based on clinical, biochemical and imaging data and confirmed by histology and immunohistochemistry (IHC). The presence or absence of endocrinological signs, clinically divides PA into functional and non-functional types. Generally, non-functioning adenomas manifest with compressive symptoms and signs: headache and visual field defect [2].

There are different classification systems of PA, depending on imaging, histology, IHC and electron microscopy. Currently, the most widely used is the IHC classification that classifies PA into lactotrophic (PRL), somatotrophic (GH), gonadotrophic (FSH/LH), corticotrophic (ACTH), thyrotrophic (TSH) and null cell adenomas [3]. Non-functional adenomas are represented by FSH/LH and null cell adenomas. This classification enables effective therapeutic management of patients with PA, which may include surgery, medical treatment and/or radiotherapy [4,5].

In our country, IHC diagnosis of PA is very restricted, first and foremost because IHC with all the needed hormonal antibodies is very expensive and also, because precise histological diagnosis on routine staining is impossible.

Several years before the implementation of IHC, a special staining named 'Herlant's tetrachrome staining' (HTCS) was used to differentiate between chromophore and chromophobe cells and between different chromophore cell types [6,7]. Applied in the diagnosis of PA, it can differentiate between functional and non-functional adenomas. This staining, which is much cheaper than IHC was not widely performed, mostly because of technical difficulties.

The purpose of this paper is to bring into discussion this staining method, to highlight its benefits, to improve the technical procedures and to establish a protocol, which combining both HTCS and IHC, facilitates the diagnosis of PA and, especially, substantially reduces the costs.

Methods

Normal pituitary glands were obtained from two autopsy cases from the Department of Pathology of the County Emergency Clinical Hospital of Tîrgu Mureş, Romania. The tissues were immediately fixed in formol and embedded in paraffin. To carry out the staining, the tissue fragments were processed in the Department of Histology of the University of Medicine and Pharmacy of Tîrgu Mureş.

Tissue sections were dewaxed in xilene and dehydrated with ethanol of different degrees of concentration. Herlant's tetrachrome staining was performed, involving several steps. The optimal time of staining and concentration of the solutions was established for each step of the staining.

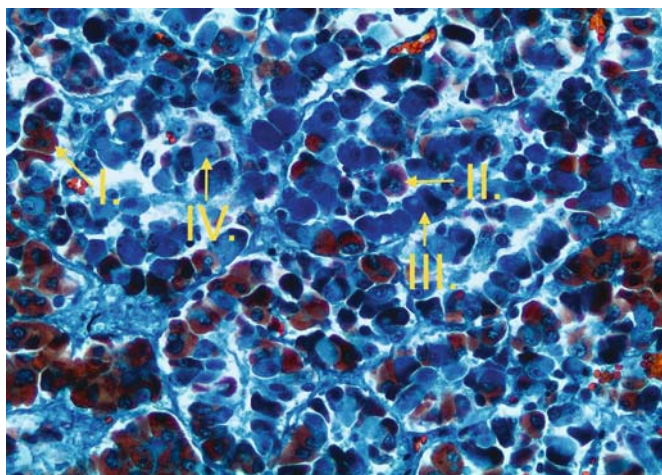


Fig. 1. Normal pituitary gland: I. GH-secreting cell, II. PRL-secreting cell, III. ACTH-secreting cells, IV. Chromophobe cell. Herlant's tetrachrome staining, original magnification x 20.

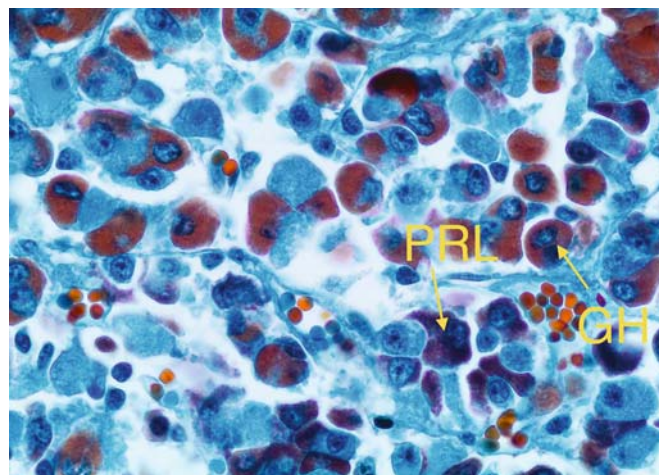


Fig. 2. Normal pituitary gland: orange binucleate GH-secreting cell and red-violet PRL-secreting cell with multiple cell processes. Herlant's tetrachrome staining, original magnification x 40.

Results

The best results were obtained using the following technique:

1. Staining with Erythrosine solution 1% – 15 minutes – quick rinse with distilled water
2. Staining with Mallory II solution (pH = 4) – 20 minutes (preparation: aniline blue, water soluble (0.5 g) + orange G (2 g) + distilled water (100 ml) – after warm dissolution and subsequent cooling, 8 ml of acetic acid was added).
– longer rinse with distilled water
3. Staining with Acid Alizarine Blue solution – 20 minutes (preparation: acid alizarine blue (0.5 g) + aluminum sulfate or chloride (10 g) + distilled water (100 ml) – boiling with a little distilled water for about 3 minutes, until it becomes a blue violet solution; cool and make up to 100 ml; filter after 24 hours).
– quick rinse with distilled water
4. 5% aqueous solution of Phosphomolybdic Acid – 15 minutes: GH-secreting cells become intense red.
5. 1% alcoholic solution of Phosphomolybdic Acid (70% ethanol) – a few seconds: watching under the microscope the transition of GH-secreting cells from intense red to orange.
6. 1% alcoholic solution of Phosphomolybdic Acid (90% ethanol) – quick pass.

The following staining results were obtained:

Among the chromophore cells, GH-secreting cells stained in orange, PRL-secreting cells in red-violet and ACTH-cells in dark blue. Chromophobe cells stained light blue. These cells can be FSH/LH-secreting cells, sparsely granulated cells or null cells, namely any chromophore cell which has released its granules (Figure 1). TSH-secreting cells are also chromophobe, but with a dark blue staining emphasizing the cell membrane.

Besides this very characteristic staining, these cells could be identified also due to some of their morphological cha-

racteristics: GH-secreting cells can be binucleated, PRL-secreting cells are elongated, with multiple cell processes (stellate cell), which intimately surround chromophobe cells (gonadotrophs) (Figure 2). In FSH/LH secreting cells, the nucleus is often placed eccentrically, at one pole of the cell. ACTH-secreting cells are recognized by the presence of a large unstained perinuclear vacuole, while TSH-secreting cells are large and polymorphous.

Discussion

This article attempts to bring into discussion HTCS, its important role in the diagnosis of PA with the great advantage of substantially reducing the costs of IHC, especially for functional PAs.

HTCS was used before IHC and is still used in some laboratories in association with specific hormonal antibodies. To our knowledge, it has never been used in Romania for PA diagnosis. Also, we found very little data in the literature.

Table I. Diagnosis protocol for pituitary adenomas

Type of PA	Step 1: HTCS and suggestive morphological aspects	Step 2: IHC (hormonal antibodies)
1. GH	Orange cells, some binucleated ones	anti-GH, -PRL ± -TSH
2. PRL	Red-violet cells	anti-PRL, -GH ± -TSH
3. ACTH	Dark blue cells, pseudorosettes around vascular channels, multiple crooke cells in peritumoral pituitary tissue	anti-ACTH, -FSH, -LH
4. TSH	Light blue cells with a dark blue reaction underlining the cell membrane, large and pleomorphic cells, stromal fibrosis	anti-TSH, -GH, -PRL
5. Sparsely granulated (GH, PRL, ACTH)	Light blue cells	anti-FSH, -LH, -ACTH, -GH, -PRL, ± -TSH
6. FSH/LH	Light blue cells, pseudorosettes around vascular channels	anti-FSH, -LH, -ACTH, -GH, -PRL, ± -TSH
7. null cell	Light blue cells	anti-FSH, -LH, -ACTH, -GH, -PRL, ± -TSH

Its important role is due to the fact that it can differentiate between two types of acidophilic cells: GH-secreting cells, stained in orange, and PRL-secreting cells, stained in red-violet. Also, it can distinguish between two types of basophilic cells: ACTH-secreting cells, which stain in dark blue, and all chromophobe cells (FSH/LH-secreting cells, sparsely granulated cells or null cells), which are light blue. TSH cells are easily recognizable by their dark blue staining, emphasizing the cell membrane [6,7].

The results, illustrated above, were performed on normal pituitary tissue, but these staining features can be extrapolated to the diagnosis of PAs, as they consist of a proliferation of such cells. Based on the fact that HTCS and the morphological features can identify at least some PA, we propose a two-step protocol in the diagnosis of these pituitary tumors:

- First step: the use of HTCS. If the cells of the PA stain orange, red-violet or dark blue, the diagnosis of the PA can be made.
- Second step: IHC staining with specific hormonal antibodies, chosen according to the results of HTCS, in close correlation with the morphological aspects, as shown in Table I.

Conclusion

The great benefit of HTCS is its use in functional PAs. It can identify GH, PRL, ACTH and TSH adenomas according to the cell type staining. Unfortunately, it cannot differentiate gonadotroph adenomas from null cell adenomas

and from GH, PRL and ACTH adenomas with sparsely granulated cells. In these cases, only IHC can establish the precise diagnosis. Therefore, a two-step protocol was proposed: first step HTCS, and second step IHC. This protocol enables the use of two, maximum three antibodies, instead of six, needed for a precise PA diagnosis. Thus, its use could play an important role in reducing the costs in the pathology laboratory, especially for functional PAs.

Acknowledgement

This paper is partly supported by the Sectorial Operational Programme Human Resources Development (SOP HRD), financed from the European Social Fund and by the Romanian Government under the contract number POSDRU 80641.

References

1. Cooper O, Melmed S. Subclinical hyperfunctioning pituitary adenomas: The silent tumors. *Best Pract Res Clin Endocrinol Metab.* 2012;26(4):447-60.
2. Jaffe CA. Clinically non-functioning pituitary adenoma. *Pituitary.* 2006;9:317-321.
3. Asa SL. Tumors of the pituitary gland. AFIP atlas of tumor pathology. American Registry of Pathology, Washington, DC, 2011, 55-172.
4. Colao A, Auriemma RS, Lombardi G, Pivonello R. Resistance to somatostatin analogs in acromegaly. *Endocr Rev.* 2011;32:247-271.
5. Biller BM, Colao A, Petersenn S, Bonert VS, Boscaro M. Prolactinomas, Cushing's disease and acromegaly: debating the role of medical therapy for secretory pituitary adenomas. *BMC Endocr Disord.* 2010;17(10):10.
6. Holmes RL, Ball JN. The pituitary gland: A comparative Account. Cambridge University Press, London 1974, 26-54.
7. Harris GW, Donovan BT. The pituitary gland. University of California Press, Berkeley and Los Angeles, California 1966, 147-233.