

## CASE REPORT

# The value of histopathological diagnosis in rupoid psoriasis accompanied by fever. A case report and a review of the literature

Morariu SH<sup>1</sup>, Badea MA<sup>2\*</sup>, Vartolomei MD<sup>3</sup>, Badea Iudita Maria<sup>4</sup>, Cotoi OS<sup>5</sup>

<sup>1</sup> Department of Dermatology, University of Medicine and Pharmacy Tîrgu Mureş, Romania

<sup>2</sup> Dermatology Clinic, County Hospital Tîrgu Mureş, Romania

<sup>3</sup> Department of Molecular and Cell Biology, University of Medicine and Pharmacy Tîrgu Mureş, Romania

<sup>4</sup> Anesthesiology and Intensive Care Medicine Clinic, Emergency County Hospital Tîrgu Mureş, Romania

<sup>5</sup> Department of Pathophysiology, University of Medicine and Pharmacy Tîrgu Mureş, Romania

Psoriasis is a common dermatosis, however the rupoid type is considered as an exceptional form of this disease. Rupoid scabs are very rare in dermatological daily practice, usually being seen as secondary to syphilis in immunosuppressed patients. Rupoid psoriasis is characterized by thick and multilayered crusts that are resistant to local therapy and present a sudden onset. Severe arthropathy is a common manifestation. We did not find in literature any association of rupoid psoriasis with intermittent fever.

We present the case of a patient who exhibited a rush of rupoid boards with severe arthralgia accompanied by intermittent fever. The suspicion of malignant syphilis was raised considering the clinical signs and symptoms and the specific social context of STDs. This suspicion was unconfirmed by TPHA negative reaction and histopathological appearance that showed changes typical of psoriasis. Clinical manifestations were successfully controlled with methotrexate.

**Keywords:** psoriasis, rupoid scab, rupoid crust, arthralgia

Received: 16 November 2014 / Accepted: 15 December 2014

## Introduction

Psoriasis is an inflammatory dermatosis of unknown cause, presenting a chronic evolution and a great clinical variability. Rupoid type is an extremely rare form, being reported in only a few publications in the literature. The term rupoid refers to small plates (2-5cm) covered with thick, hard and multilayered crusts [1]. This type of injury is especially common in secondary syphilis, malignant form and in immunocompromised patients [2]. These rupoid crusts were also cited in Reiter's syndrome, Norwegian scabies, disseminated histoplasmosis and photosensitivity reactions associated with aminoaciduria [3]. In a PUBMED search we found only 10 reports about rupoid psoriasis.

## Case presentation

We present the case of a 45 year old patient who required skin examination for a disseminated eruption occurred seven days before, consisting of erythematous plaques covered by thick crusts, tough and multilayered. Clinical examination revealed also palmar-plantar lesions, dactylitis and onycholysis. Skin lesions were accompanied by fever spikes (38-39°C) and strong intermittent arthralgia in the knees, hands, feet, sacroiliac joints. Joint manifestation started four months before presentation. From patient history, we recorded casual and unprotected sex, the presence of skin lesions on the penis six months before that healed

spontaneously. Based on clinical history, skin lesions and symptoms associated, the diagnosis of probability was malignant syphilis. This was unconfirmed by TPHA negative reaction. Other significant laboratory data for this case were: leukocytosis (12.300/mm<sup>3</sup>) and increased erythrocyte sedimentation rate (60 mm/h). Serological reaction for HIV 1.2 was negative. We performed two skin biopsies and the histopathological examination showed changes typical of psoriasis with remarkable microabscesses Munro-Sabouroud, parakeratosis, elongation and union of interpapillary ridges, and granular layer disappearance. We initiated treatment with methotrexate 15mg/week with favorable response after 2 months of therapy. Currently the patient is discharged from our clinic and the disease is controlled by methotrexate 5 mg/week.

## Discussion

Rupoid crusts were observed for the first time in 1859 by Bazin, in secondary syphilis [4]. A complete outline of their clinical appearance was given in the last decade of the XXth century, by Neisser and Haslund [5, 6].

Rupoid psoriasis belongs to the rare forms of the disease. It was individualized as clinical form by Grzybowski in 1948 [7]. Along with the elephantine shape and form ostracee they are hyperkeratotic forms of psoriasis characterized by ineffective local treatment due to minimum absorption of topical therapy [8]. There was described only one case with favorable response to topical therapy with clobetasol spray 0.05 [9].

\* Correspondence to: Mihail Alexandru Badea  
E-mail: badeamihai2011@yahoo.com

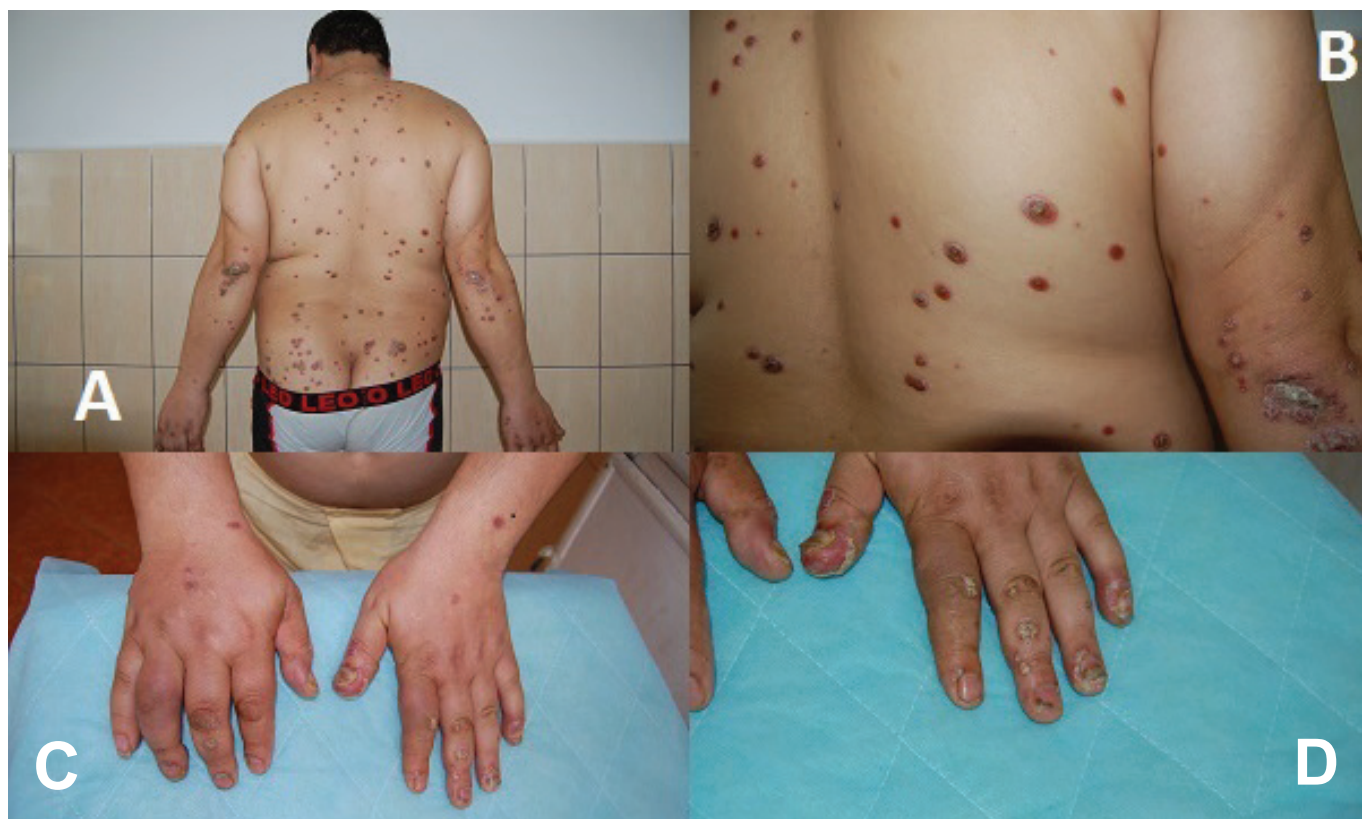

Fig. 1. Clinical aspects. A) Disseminated eruption of rupoid crusts B) Rupoid crust – detail C) Dactylitis D) Onycholysis

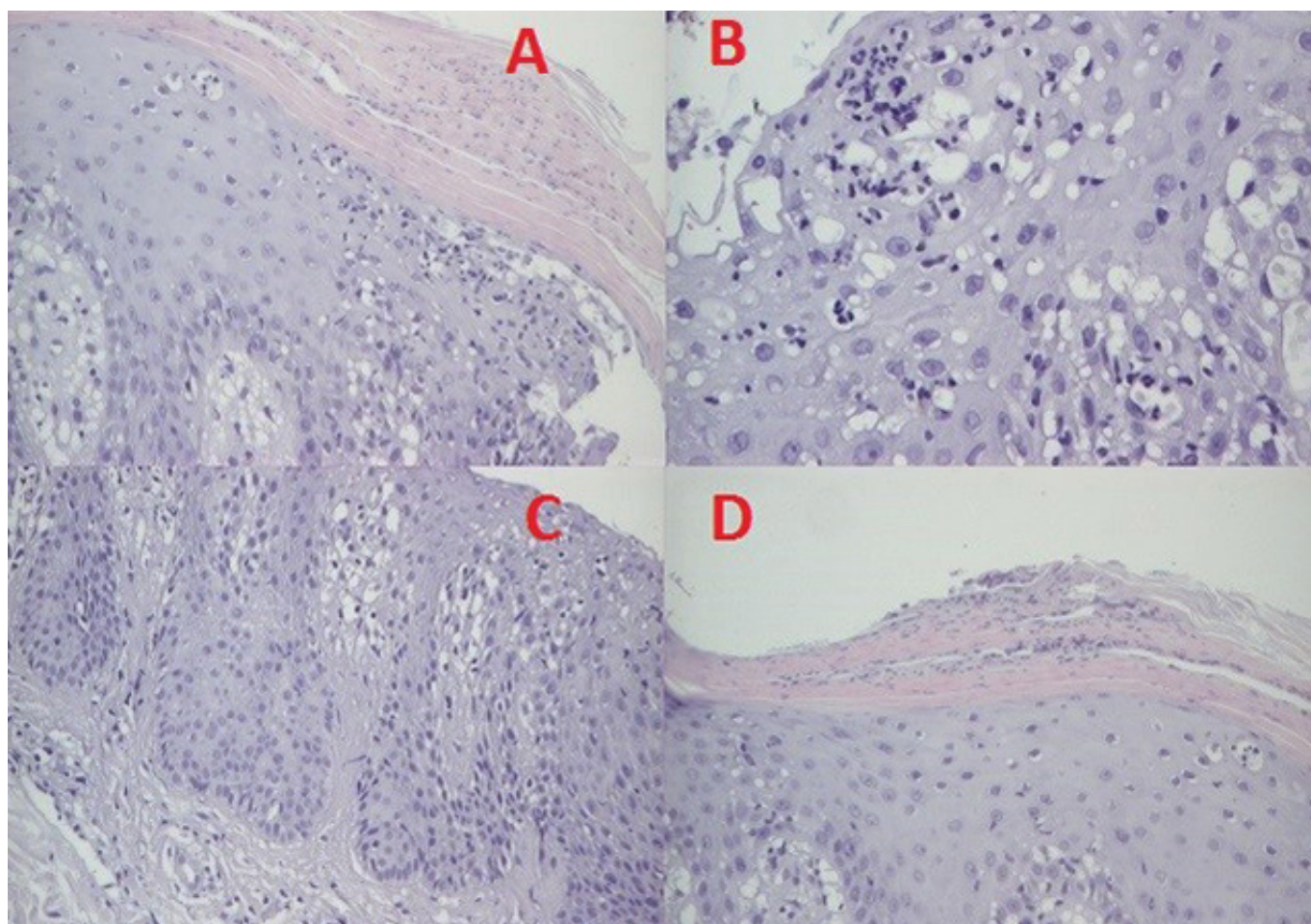


Fig. 2. Histological aspects A,B) Micro abscesses Munro-Sabouraud, C) elongation and union of interpapillary ridges D) Absence of the granular layer and parakeratosis

Arthropathy is a common manifestation. Murakami *et al* described a case of rupoid psoriasis with severe arthropathy, limited only at knee and right hand, which was effectively treated with low doses of corticosteroids. In this case, histopathological examination was significant for diagnosis by the abundance of Munro micro abscesses [10]. Wang described a case of sacroiliac arthropathy which was effectively treated with methotrexate. As in our case, joint manifestations preceded rash with six months [11]. A very interesting case was described by Zhu *et al* with malignant syphilis which present two localized rupoid plates evolving for 10 years, accompanied by fever and arthropathy in the right knee. In analogy with our case, they suspected rupoid psoriasis but immunohistochemical examination displayed evidence of spirochetes [12]. Was described also a case of rupoid psoriasis with out arthropathy, successfully treated with emollients and Photo chemotherapy (PUVA) [8]. Nečas and Vašků reported a case of patient with a presence of 21 years old lesions of rupoid psoriasis, with arthropathy that started 9 years after the onset of rash. Both lesions were controlled therapeutic by administration of Ustekinumab [13].

Costa *et al.* report a case of Norwegians cabbies with aspect of rupoid psoriasis, a form characterized by thick crusts that occurs in immunocompromised patients, but the female patient had extensive hyperkeratotic plaques, hard and multilayered with no immunosuppression associated [14].

Rupoid scabs have been described in the photosensitivity reactions associated with aminoaciduria. In 1978, Haim *et al* described the appearance in the light exposed areas of this type of lesions, in 2 patients with aminoaciduria. One of the patients suffering from Ehlers Danlos syndrome and other with plaque psoriasis [15,16].

There is a report in which *Histoplasma capsulatum* infection in immunocompromised patient lead to extensive rupoid crust. They were well defined in the face area. It is interesting that the patient had liver damage, this condition could be found also in aminoaciduria, psoriasis or syphilis patients [17]

## Conclusion

Rupoid psoriasis is a rare form of the disease and can accompany the intermittent fever. It requires differential diagnosis with other dermatoses which show rupoid crusts, primarily with secondary syphilis. Methotrexate is an effective therapy that controls both articular manifestations and skin lesions.

## References

1. Ladizinski B, Lee KC, Wilmer E *et al.* A review of the clinical variants and the management of psoriasis. *Adv Skin Wound Care.*2013; 26(6):271-284.
2. Bhagwat PV, Tophakhane RS, Rathod RM *et al.* Rupoid syphilis in a HIV patient. *Indian J DermatolVenereol Leprol.*2009; 75(2):201-202.
3. Chung HJ, Marley-Kemp D, Keller M. Rupoid psoriasis and other skin diseases with rupoid manifestations. *Cutis.* 2014;94(3):119-121.
4. Rutowitsch MS. Sifilismalignaprecoce. *Anaisbrasileiros de Dermatologia.*1980;55: 147-150
5. Neisser A. Malignant syphilis. *Br J Dermatol* 1897;9:11-26.
6. Haslund A. Syphilis maligna. *ArchivfürDermatologie und Syphilis* 1897;38:345-392.
7. Grzybowski M. *Diseases of the Skin: Handbook for Practitioners and Students.* Vol 2. Warsaw, Poland: Institute of Medical Science Publishing; 1948.
8. Salamon M, Omulecki A, Jedrzejowska AS. Psoriasis Rupioides: A Rare Variant of a Common Disease. *Cutis.* 2011; 88:135-137.
9. Feldman SR, Brown KL, Heald P. 'Coral reef' psoriasis: a marker of resistance to topical treatment. *J Dermatolog Treat.* 2008; 19(5):257-258.
10. Murakami T, Ohtsuki M, Nakagawa H *et al.* Rupoid psoriasis with arthropathy. *ClinExpDermatol.* 2000 Jul; 25(5):409-412.
11. Wang JL, Yang JH. Rupoid psoriasis associated with arthropathy. *JDermatol.* 1997; 24(1):46-49.
12. Zhu K, Zhou Q, Han R *et al.* Acute monoarthritis in a delayed diagnosis of syphilis patient with persistent rupoid psoriasis-like lesions. *BMC Infect Dis.* 2012; 12:338.
13. Necas M, Vašků V. Ustekinumab in the treatment of severe rupoid psoriasis: A case report. *ActaDermatovenerol Alp PannonicaAdriat.* 2010;19(2):23-27.
14. Costa JB, Rocha de Sousa VL, da TrindadeNeto PB *et al.* Norwegian scabies mimicking rupoid psoriasis. *An Bras Dermatol.* 2012 Nov-Dec; 87(6):910-913.
15. Haim S, Gilhar A, Cohen A. Cutaneous manifestations associated with aminoaciduria. Report of two cases. *Dermatologica.* 1978; 156(4):244-250.
16. Szilveszter M, Albean M, Pap Z. Syndactyly as Symptome or Part of Plurimalformative Syndrome in Pediatric Patology. *Clinical and Therapeutical Considerations.* Acta Medica Marisiensis. 2011; 57(2):121-124.
17. Corti M, Villafañe MF, Palmieri O *et al.* Rupoid histoplasmosis: first case reported in an AIDS patient in Argentina. *Rev Inst Med Trop Sao Paulo.* 2010; 52(5):279-280.