ORIGINAL ARTICLE

The Role of Sonoelastography in the Differential Diagnosis of Breast Lesions

Gheonea Ioana[1], Popescu Camelia[2], Bondari A.[1]

[1] Radiology and Imaging Department, University of Medicine and Pharmacy Craiova
[2] ENT Department, Emergency Hospital Craiova

Background: Tissue elasticity imaging technology is expected to be a new modality for breast diagnosis, based on hardness as a tissue characteristic that is affected by tissue disease such as cancer.
Aim: To assess the value of sonoelastography in the differential diagnosis of breast lesions.
Patients and method: We included in this prospective study 59 patients diagnosed with breast lesions between January 2009 and January 2010. All the patients were examined in the supine position and the B mode ultrasound image was displayed alongside the elastography strain image. An EUS Hitachi EUB 8500 ultrasound system with an embedded elastography module (Hitachi Medical Systems Europe Holding AG, Zug, Switzerland) and a 6.5-MHz linear probe was used to obtain the B mode and elastography strain images. The elastography strain images were scored according to the Tsukuba elasticity score.
Results: For assessment of sonoelastography role in differential diagnosis of breast lesions, we performed ROC analysis, and we obtained a sensitivity of 89.7%, and a specificity of 92.9% (area under the ROC curve = 0.924, 95% CI = 0.822–0.977 and p = 0.0001).
Conclusions: Elastography is a fast, simple method which can complement the conventional US. Elastography is promising, and with future improvements in the technology, this imaging modality will become an invaluable tool for the diagnosis of breast diseases in the clinical setting.

Keywords: breast cancer, ultrasound elastography, ROC curves

Introduction

Tissue elasticity imaging technology is expected to be a new modality for breast diagnosis, based on hardness as a tissue characteristic that is affected by tissue disease such as cancer. Different approaches of elasticity imaging have been investigated, and at present some are at the stage of developing a practical system [1,2,3]. Sonoelastography (SE) exploits the theory that benign and malignant breast lesions have inherent differences in firmness. Strain images display the relative stiffness of lesions compared with the stiffness of surrounding tissue [4]. Stiffer areas deform less easily than do their surroundings and are depicted as dark on strain images, whereas softer areas deform more easily than do their surroundings and are depicted as light.

Materials and methods

In this study, a prospective trial was conducted in which patients presenting with a breast lesions were assessed with conventional B mode ultrasound. Those confirmed to have breast lesions were assessed also with elastography after an informed consent was obtained. The patients were examined in the supine position with the arm on the examination side placed behind the head. The ultrasound probe lubricated with gel was placed on the breast over the lesions. The B mode ultrasound image was displayed alongside the elastography stain image to ensure that the assessment was made in the area of interest. A slight, rhythmic compression-decompression movement is applied, holding the scan plane always perpendicular on the skin surface, the anterior margin of the lesion and the chest wall. The region of interest (ROI) must be set to include the lesion, subcutaneous layers and pectoralis muscle, without costal arches. The images were acquired and the elastography strain images scored according to the elasticity score. An EUS Hitachi EUB 8500 ultrasound system with an embedded elastography module (Hitachi Medical Systems Europe Holding AG,Zug, Switzerland) and a 6.5-MHz linear probe was used to obtain the B mode and elastography strain images. The elastography strain images were scored according to the Tsukuba elasticity score developed by Itoh and Ueno [4]. Score 1 (predominantly green) is used for lesions which present similar deformability to the surrounding breast parenchyma, score 2 lesions are those with an inhomogeneous deformability, the overall appearance being a mosaic pattern of green and blue. Score 3 is attributed to lesions with elastic (green) periphery and stiff (blue) core. Score 4 is used for rigid (blue) nodules, not including the echoic halo. Score 5 is reserved for cases with no tissue displacement secondary to compression, within the lesion itself and also within the adjacent tissues (echoic halo included) which appear blue on the elasticity image. The histology of all the nodules was established with fine needle aspiration cytology (FNAC), core biopsy or excision biopsy, according to clinical indications.

Results

We included in the study 59 patients investigated between January 2009 and January 2010, with breast lesions confirmed on ultrasound. The average age of the women was 45 years. There were 28 benign (47.75%) and 29 malignant lesions (49.15%). The most common histologies of the benign nodules were fibroadenoma, cysts and fibro-

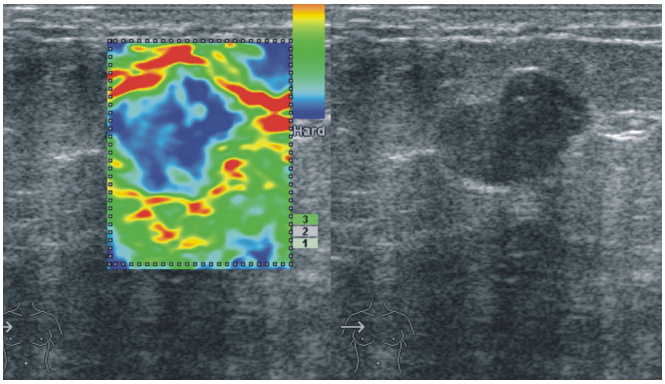

Fig. 1. A lesion in the right breast predominantly blue on elastography with an elasticity score of 3 in a 54 year old patient which was diagnosed as a calcified fibroadenoma

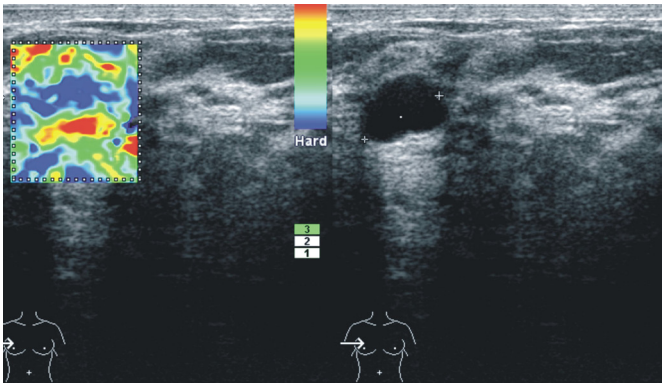

Fig. 2. A typical elastographic appearance (blue, green, red) of a cyst in a 23 year old patient

cystic change. Of the malignant nodules, the most common lesion was infiltrative ductal carcinoma. Fibroadenomas appeared softer or with the same elasticity as adjacent glandular tissue with elasticity score of 1 or 2 (Figure 1). Breast cysts had a characteristic three layer aspect: blue-green-red (BGR), blue being the superficial color and red the deep one, with an elasticity score of 1 (Figure 2). The fbro-cystic nodules had an elasticity aspect similar to surrounding parenchyma. Breast carcinomas had high elasticity scores of 4 or 5 and their appearance was larger on the elastography image as compared to the gray scale one, due to better visualization of the surrounding desmoplastic and microscopically invaded tissue (Figure 3). To calculate the sensitivity and specificity of elastography, lesions with elasticity scores 1–3 were classified as benign, while those with scores of 4 or 5 were classified as malignant. For assessment of sonoelastography role in differential diagnosis of breast lesions, we performed ROC analysis (Figure 4), and we obtained a sensitivity of 89.7%, and a specificity of 92.9% (area under the ROC curve=0.924, 95% CI =0.822-0.977 and p=0.0001).

Discussion

The interpretation of breast nodules detected on B mode ultrasound (US) relies mainly on morphological criteria. As a result, additional sonographic criteria were developed to improve the accuracy of US including Doppler and harmonic imaging [5,6]. Since the last decade, there has been an interest in imaging the elasticity of biological tissues as a complement to standard anatomical imaging. US elastography may aid in the differentiation of benign from malignant solid breast masses. This technique exploits the theory that benign and malignant breast lesions have inherent differences in firmness. Strain images display the relative stiffness of lesions compared with the stiffness of surrounding tissue. Stiffer areas deform less easily than do their surroundings and are depicted as dark on strain images, whereas softer areas deform more easily than do their surroundings and are depicted as light [7,8].

The first clinical results of sonoelastography (SE) were published in 1997– 2001 [9], but only in 2003–2004 the development of US equipment with dedicated software for real time processing enabled SE utilization simultaneously with routine US examinations [10]. For characterization of breast lesion, two elasticity scores are proposed: Tsukuba score developed by Itoh and Ueno [4] and a second one designed by the Italian Research Group after Locatelli M, Rizzatto G et al. [5].

In this study, we reported that when a cutoff point of 3 was used, elastography -on the use of real-time ultrasound elastography. Thomas et al. [11] reported sensitivity of 77.6% and 79.6% and specificity of 91.5% and 84.5%,

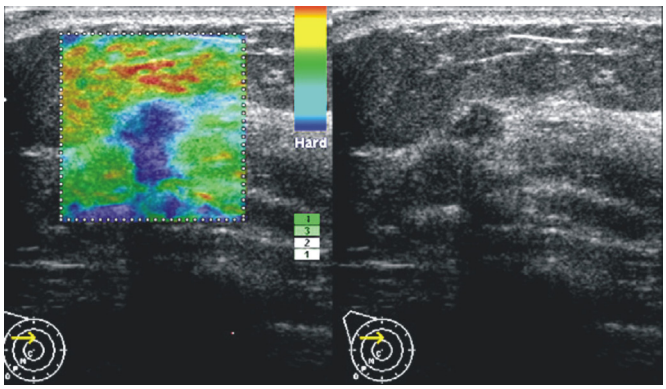

Fig. 3. Invasive ductal carcinoma in a 43-year-old woman. On elasticity image, the lesion and the surrounding tissue were coloured blue, with an elasticity score of 5

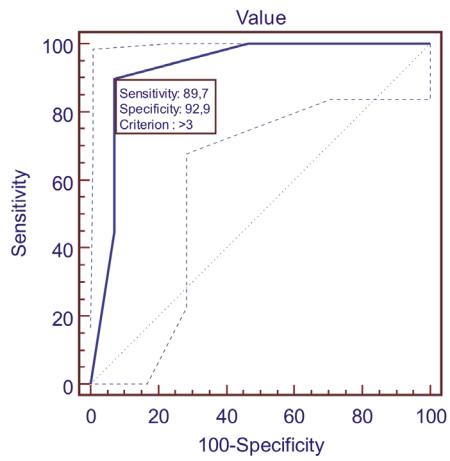

Fig. 4. Sensitivity, specificity values on ROC analysis for elastography (MedCalc Software 9, 2008, Mariakerke, Belgium)

respectively, relating to two examiners evaluating 108 breast lesions. Itoh et al. [4], reported high sensitivity of 89.3% and 83.3% and specificity of 93.1% and 86.7% in the first and second stages of their study of 111 lesions. Zhi et al. [12] recently reported even better results: ultrasound elastography was found to be the most specific (95.7%) and had the lowest false-positive rate (4.3%). Elastography scores certainly provide additional information to that provided by B-mode images. Ultrasound detects many non-palpable lesions, and it is less specific when used for breast screening. Elastography may be helpful to obtain additional information based on which we can decide whether we should request the women to return for additional examination. Moreover, in clinical situations, elastography may be useful for determining whether to apply interventional methods or conduct follow-up. In addition, although it is sometimes difficult to differentiate between scores 2 and 3 (because their difference is distribution of blue area), it is easy to judge a lesion as having score 1 because no blue area is observed. Ultrasound elastography is less sensitive than standard US when dealing with non-focal anomalies and is not indicated for the evaluation of post¬operative changes, diffuse lesions or large ones, which exceed the probe length or its field of view (FOV) [13,14]. Elastography is also limited in very dense, fibrous parenchyma, in case of hematomas or breast implants [15].

Conclusions

Real-time breast ultrasound elastography is a fast, simple method which can improve the sensitivity and positive predictive value of conventional US when diagnosing BI-RADS 3 and 4 focal lesions. It can lead to a decreased rate of unnecessary biopsies or futile re-examinations

Furthermore, elastography can provide information which is difficult or impossible to collect with conventional ultrasound alone. It is therefore an improved complementary method which can be used along with other imaging modalities in breast diagnosis. For sure, this imaging modality will become an invaluable tool for the diagnosis of breast diseases in the clinical setting.

References

1. Krouskop TA, Wheeler TM, Kallel F, et al., Elastic moduli of breast and prostate tissues under compression. Ultrason Imaging 1998, 20:260-274.
2. Ophir J, Cespedes I, Ponnekanti H, et al., Elastography: a quantitative method for imaging the elasticity of biological tissues. Ultrason Imaging 1991, 13:111-134.
3. Klauser AS, Faschingbauer R, Jaschke WR. Is sonoelastography of value in assessing tendons? Semin Musculoskelet Radiol. 2010;14:323-33
4. Itoh A, Ueno E, Tohno E, et al. Breast Disease: Clinical Application of US Elastography for Diagnosis. Radiology 2006; 239: 341-350.
5. Rizzatto G. Real-time elastography of the breast in clinical practice - the italian experience. Medix Hitachi Supplement 2007: 12-15.
6. Itoh A. Review of the techniques and diagnostic criteria of breast ultrasound elastography. Medix Hitachi Supplement 2007: 8-11.
7. Hong AS, Rosen EL, Soo MS, et al. BIRADS for sonography: positive and negative values of sonographic features. AJR Am JRoentogenol 2005; 184: 1260–1265.
8. E. Ueno, T. Shiina, M. Kubota, K. Sawai (Eds.). Research and Development in Breast Ultrasound. In Springer-Verlag (eds). In Vivo Breast Examination by Real-Time Freehand Elasticity Imaging System, Tokyo, 2005, 7-16.
9. Garra BS, Cespedes EI, Ophir J, Spratt SR, Zuurbier RA, Magnant CM, Pennanen MF Elastography of breast lesions: initial clinical results. Radiology 1997, 202:79–86.
10. Konofagou EE. Quo vadis elasticity imaging? Ultrasonics 2004, 42: 331–336.
11. Thomas A, Fischer T, Frey H, et al. Real-time elastography—an advanced method of ultrasound: first results in 108 patients with breast lesions. Ultrasound Obstet Gynecol 2006; 28: 335–340.
12. Zhi H, Ou B, Luo BM, et al. Comparison of ultrasound elastography, mammography, and sonography in the diagnosis ofsolid breast lesions. J Ultrasound Med 2007; 26: 807–815.
13. Thomas A, Kummel S, Fritzsche F, et al. Real-time sonoelastography performed in addition to B-mode ultrasound and mammography: improved differentiation of breast lesions? Acad Radiol 2006; 13: 1496-1504.
14. Scaperrotta G, Ferranti C, Costa C, et al. Role of sonoelastography in non-palpable breast lesions. Eur Radiol. 2008;18:2381-2389
15. Giuseppetti GM, Martegani A, Di Cioccio B, Baldassarre S. Elastosonography in the diagnosis of the nodular breast lesions: preliminary report. Radiol Med 2005; 110: 69-76.