

The Use of Heterologous Bovine Pericardium in the Closure of Bronchial Stump After Lung Resections, Experimental Study

Bud V¹, Suciuc B¹, Copotoiu Ruxandra², Sin Anca³, Cotoi O³, Butiurcă V⁴, Cordos B⁵, Brânzaniuc Klara⁶, Copotoiu C¹

¹ 1st Surgical Clinic, County Emergency Clinical Hospital, Tîrgu Mureş, Romania

² ICU, County Emergency Clinical Hospital, Tîrgu Mureş, Romania

³ Department of Anatomopathology, County Emergency Clinical Hospital, Tîrgu Mureş, Romania

⁴ Student, University of Medicine and Pharmacy, Tîrgu Mureş, Romania

⁵ Veterinarian, University of Medicine and Pharmacy, Tîrgu Mureş, Romania

⁶ Department of Anatomy, University of Medicine and Pharmacy, Tîrgu Mureş, Romania

Introduction: There are many authors who have devoted their time and expertise to find creative ways for an ideal suture of bronchial stump. Despite their efforts, the bronchial fistula rate reported in the specialty literature remains high, between 2–16%, depending on the author. There are two methods for closing bronchial stumps: manual and mechanical suture. The aim of this study was to experiment a new technique for closing bronchial stumps after lung resections.

Material and method: In order to carry out this study we used 15 common rabbits. We performed left inferior lobectomy in these rabbits. These rabbits were divided into three groups according to the methods used to close the bronchial stump. We used three methods for closing the bronchial stump: simple running suture, suture of the bronchial stump using two vicryl mesh patches and suture of the bronchial stump using two heterologous bovine pericardial patches.

Results: We did not notice any cases of bronchial stump fistula. The most important changes that appear during the bronchial stump healing are: inflammatory response, angiogenesis, hyperplasia of the smooth muscle fibres, migration of fibroblasts and fibrogenesis.

Conclusions: Healing signs appeared on all examined samples, but they were more intensive in the group where we used the heterologous bovine pericardium for closing the bronchial stump. Some further studies are necessary to examine the effectiveness of the use of heterologous bovine pericardium to protect the bronho-anastomosis.

Keywords: heterologous bovine pericardium, bronchial stump, fistula

Received: 15 April 2011 / Accepted: 5 August 2012

Introduction

Thoracic surgery is regarded to be a branch of surgical interventions with the highest rate of mortality and morbidity. One of the main causes of increased morbidity and mortality in patients who underwent pulmonary resection is the occurrence of bronchial fistula. There are many authors who have devoted their time and expertise to find creative ways for an ideal suture of bronchial stump. Despite their efforts, the bronchial fistula rate reported in the literature remains high, between 2–16%, depending on the author.

There are two methods for closing the bronchial stump: manual suture and mechanical suture. The aim of this study is to experiment a new technique for closing the bronchial stump after lung resections.

Material and methods

The study was conducted in the Bio Base of the University of Medicine and Pharmacy, Tg. Mures. We obtained the approval of the Ethical Research Committee of our University. For our study we used 15 rabbits. We performed left inferior lung lobectomy in these rabbits by using left thoracotomy.

Anesthesia was performed by the administration of ketamine (35mg/kg) and Xylazine (10 mg/ kg), and we also performed naso-tracheal intubation [1]. In order to maintain anesthesia we used halothane intraoperatively.

The used intraoperative fluid intake was 10 ml/kg/h.

The section of the bronchial stump was performed in block at the same time with the vessels of the left inferior lobe. At that time we could not access a microsurgery kit, which was the reason why we decided to close the bronchial stump in that manner.

The 15 rabbits were divided into 3 groups:

- ▶ Group A: 5 rabbits that underwent the bronchial stump closure using running suture with 5.0 prolene thread
- ▶ Group B: 5 rabbits that underwent the bronchial stump closure using isolated suture with 5.0 prolene thread armed with two patches of vicryl mesh placed on both sides
- ▶ Group C: 5 rabbits that underwent the bronchial stump closure using isolated suture with 5.0 prolene thread armed with two patches of heterologous bovine pericardium placed on both sides

The closure of the thorax was performed in anatomical layers. We did not use pleural drainage due to the risk of accidental extraction of the drainage tube. We applied as an alternative solution a loose suture to prevent postoperative pneumothorax.

Postoperative feeding was resumed in the second day. The experimental animals were treated with analgesics,

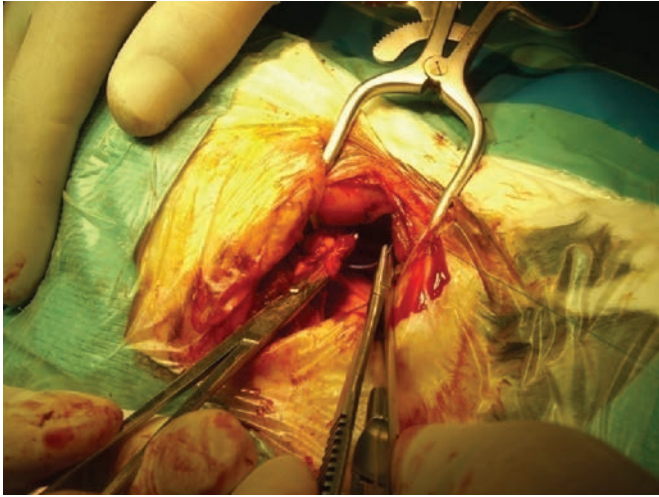


Fig. 1. Intraoperative aspect of the bronchial stump

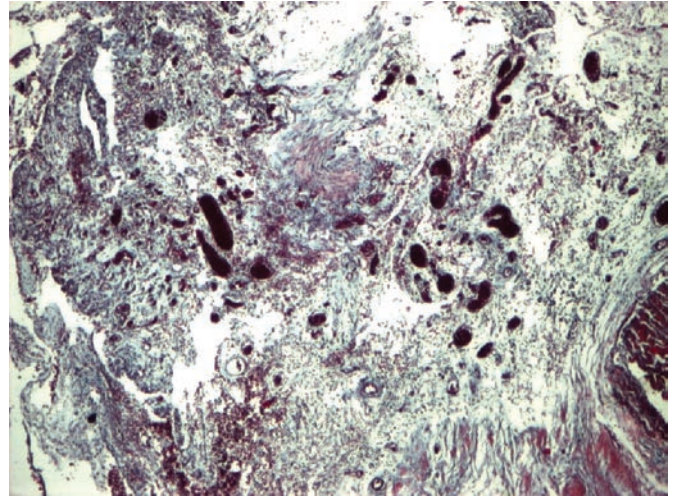


Fig. 2. Tricrom Masson, Ob 4x, bronchial stump closed using heterologous pericardium

antibiotics and anticoagulants. These animals were euthanized on postoperative day 10, by inhalation of ether.

We performed autopsy in all studied animals. During autopsy we removed the trachea in block with both lungs. The pathohistological pieces were included in paraffin then sectioned and stained by using Hematoxilin-Eozin, Tricrom-Masson and Van Giesson.

Results

The postoperative clinical evolution of the experimental animals was favourable. We had no cases of death in our group of animals. At autopsy, we found in all animals the signs of mild lung atelectasis due to the fact that we did not use the pleural drainage. We also noticed the presence of an inflammatory syndrome that affected the pleural cavity. The inflammatory syndrome has affected especially the group of animals that underwent the closure of the bronchial stump using a patch of bovine heterologous pericardium or vicryl mesh.

In those cases where the bronchial stump was closed with vicryl mesh we noticed an intense process of adhesion

between the lung and the thoracic wall and between the bronchial stump and surrounding tissues.

During the microscopic examination we observed an intense inflammatory infiltrate with multiple lymphocytes and plasma cells. We noticed this aspect on all examined preparations (Figure 2). We also observed that the most intense inflammatory response appeared in those cases where the bronchial stump was closed using heterologous pericardium.

Ten days subsequently to surgery we observed the appearance of hyperplasia in the smooth muscle fibers from the bronchial wall. We also noticed the appearance of a neo-chondrogenesis process (Figure 3). We observed that at 10 day postoperatively the granulation tissue was also present. We examined this tissue both from the endobronchial and peribronchic point of view (Figure 3). Those aspects were more obvious in case of bronchial stump closed with heterologous pericardium.

In case of lung parenchyma situated in close proximity to the bronchial stump we observed a process of bronchec-

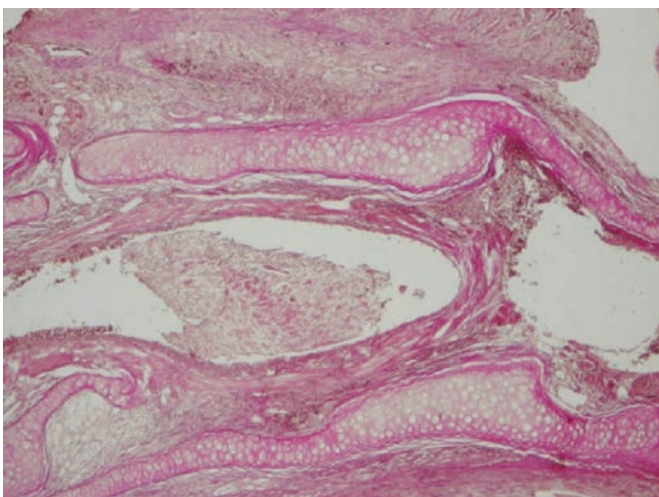


Fig. 3. Hematoxilin-Eozin, Ob 2x, bronchial stump closed using heterologous pericardium

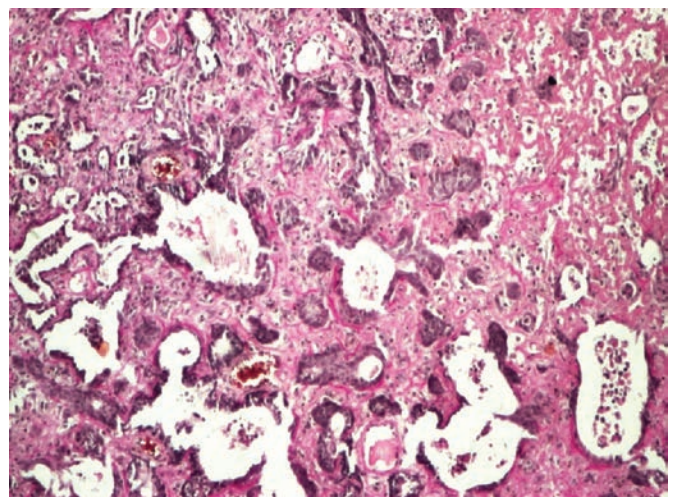


Fig. 4. Hematoxilin-Eozin - bronchial stump closed using heterologous pericardium

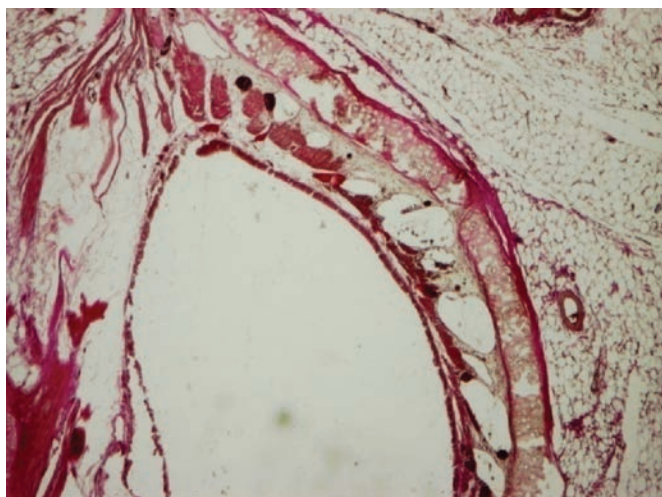


Fig. 5. Van Giesson, Ob 4x, bronchial stump closed using heterologous pericardium

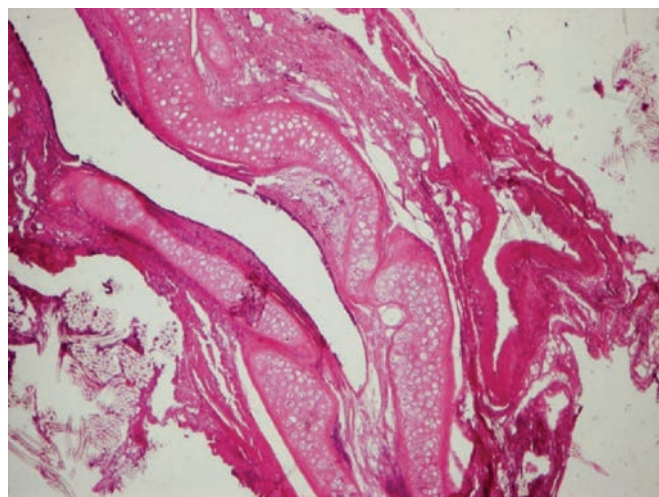


Fig. 6. Hematoxilin-Eozin, bronchial stump closed using simple running suture

tasia (Figure 4). We also noticed an increased density of the small vessels along the lamina propria and small bleedings at that level (Figure 4). This increased number of vessels was a sign that the process of angiogenesis had started.

The repairing process of the bronchial stump started 10 days after surgery. As a sign of this process we observed that the sutured zone is covered by bronchial epithelium (Figure 5). This phenomenon of re-epitelization is mostly present in cases where the bronchial stump is closed with heterologous pericardium.

The extracellular matrix was denser in those cases where the bronchial stump was closed by using simple running suture or vicryl mesh (Figure 6) compared to those in which the bronchial stump was closed by using heterologous pericardium (Figure 7). The extracellular matrix in those cases was quite loose.

Discussions

During the last 70 years multiple types of bronchial stump closures have been applied. Despite all efforts the incidence

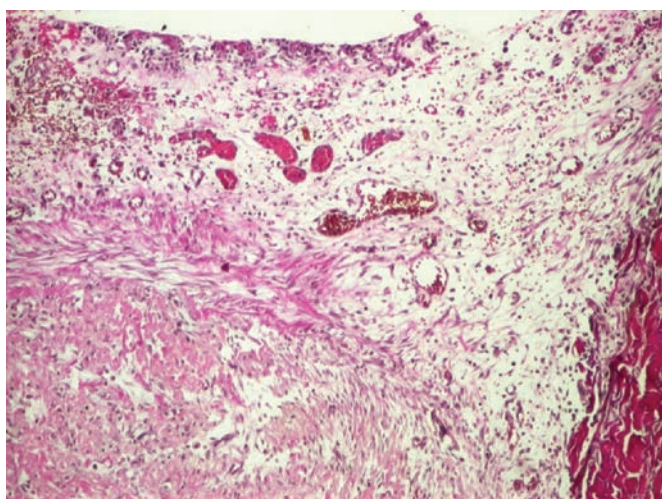


Fig. 7. Hematoxilin-Eozin, Ob 2x, bronchial stump closed using heterologous pericardium

of bronchial stump fistula is still high [2]. Our purpose was to experiment a new way of closing the bronchial stump. In order to perform this study we relied on the idea that the bronchial stump technique followed the specific steps of a normal tissue healing in our body.

Some authors consider that the formation of the granulation tissue represent the key point in the bronchial stump healing [3]. But, the achievement of an adequate bronchial stump scar is a complex process that can be affected by many factors. There are many negative factors that can influence the bronchial stump healing: insufficient vascularization of the bronchial stump, mechanical factors, immune reaction.

In 1942, Rienhoff recommended the cover of the bronchial stump using parietal pleura. Other authors recommend the cover of the bronchial stump using pectoralis major muscle flaps, diaphragm flaps, azigos vein flaps. In our study it was used the same principle for covering the bronchial stump.

Topolnitskiy (2009) considers that the external contention promotes the healing of the bronchial stump because it ensures an adequate closure of the stump.

We observed a process of adhesion of the bronchial stump to the surrounding structures in those groups where the bronchial stump was closed using heterologous pericardium or vicryl mesh. In the group where we practiced a simple running suture of the bronchial stump we did not observe this adhesion process.

The adhesion of the bronchial stump to the surrounding tissues can prevent the appearance of the pleural empiema in case of bronchial stump fistula. It is well known that the pleural empiema increases the morbidity and the mortality of patients [4].

According to the speciality literature, it is well known that the first step in the healing process is the inflammatory response. We noticed that response in our study too, but we observed that the intensity of the inflammatory response was much higher in those groups where the bron-

chial stump was closed using heterologous bovine pericardium.

Many authors consider that there is no significant difference between the manual or the mechanical suture of the bronchial stump concerning the incidence of the bronchial stump fistula [5]. On the other hand, other authors consider that the formation of granulation tissue in the bronchial stump is more evident in case of manual suture compared to the mechanical one [6].

10 day postoperatively, we observed in all examined samples the presence of neo-angiogenesis. We also observed slight bleeding in the lamina propria of the bronchus. Angiogenesis can be considered an intermediate step in the healing of the bronchial stump. The phenomenon of angiogenesis was more evident in those samples that were harvested from the bronchial stumps sutured with heterologous bovine pericardium.

In the group where the bronchial stump was closed using heterologous pericardium we observed that the extra cellular matrix was very loose compared to the other groups. We know that in the healing process fibroblasts migrate to the extracellular matrix and participate in the collagen synthesis. As the extra cellular matrix is more lax, the migration of fibroblasts occurs even easier [7,8].

We observed on the examined samples the presence of hyperplasia of smooth muscle fibers also discussed in the speciality literature by other authors [9]. We also noticed the emergence of neo-condrogenesis as a new phenomenon. We observed in the group where we used the simple running suture that the neo-condrogenesis in the bronchial stump was isolated compared to the other study groups.

The formation of the granulation tissue was present in all examined samples. In the speciality literature it is well known that the formation of the granulation tissue is a clear marker of tissue healing. We observed that the granulation tissue was present both inside and outside (surrounding it) the bronchus.

10 days postoperatively we observed that the re-epitelisation of the bronchial stump is present. The re-epitelisation of the bronchial stump is much more present in those samples where the bronchial stump is closed using heterologous pericardium. A process that is similar to re-epitelization of the bronchial stump is the re-endothelization of the heterologous bovine pericardium grafts in vascular surgery [10].

In time, the bovine heterologous pericardium undergoes calcification [11,12,13]. We did not observe the calcification of the bronchial stump in our samples probably because we euthanized our experimental animals in the 10th day postoperatively. The calcification of the bronchial stump may increase its resistance that can be favourable in the long term outcome.

It is known that the fistula of the broncho-anastomosis after lung transplantation is responsible for a mortality rate of 2–5% [14]. It is possible that the use of heterologous bovine pericardium to protect the broncho-anastomosis may reduce the incidence of broncho-anastomosis fistula in such cases.

Conclusions

The most important changes that appear in the bronchial stump healing are: the inflammatory response, angiogenesis, hyperplasia of the smooth muscle fibres, migration of fibroblasts and fibrogenesis. These changes emerged on all the examined samples, but their intensity was higher in the group where we used the heterologous bovine pericardium when closing the bronchial stump. Further studies are necessary to examine the efficiency of the heterologous bovine pericardium to protect the broncho-anastomosis.

References

1. Tranyvilli W, Thurmon JC, Grimm KA. Veterinary anesthesia and analgesia in Laboratory animals. 2007;765-785.
2. Levchenko EV, Shutov VA, Trishin A. Bronchopleural fistula – risk factors, prophylactics and treatment in oncopulmonology. *Vestn Khir Im.* 2005;3:15-22.
3. Rienhoff WF, Gannon J, Sherman I. Closure of the bronchus following total pneumectomy: experimental and clinical observation. *Ann Surg.* 1942;116:481.
4. Walsh MD, Bruno AD, Onaitis MW, Erdmann D, Wolfe WG, Toloza EM, Levin LS. The role of intrathoracic free flaps for chronic empyema. *Ann Thorac Surg.* 2011;91:865-868.
5. Vester SR, Faber LP, Kittle CF, Warren WH, Jensik RJ. Bronchopleural fistula after stapled closure of bronchus. *Ann Thorac Surg.* 1991;52:1253-1257
6. Izumi Y, Kawamura M, Gika M, Nomori H. Granulation tissue formation at the bronchial stump is reduced after stapler closure in comparison to suture closure in dogs. *Interact Cardiovasc and Thorac Surg.* 2010; 10:356-359
7. Clark RAF, editor. *The Molecular and Cellular Biology of Wound Repair.* New York: Plenum, 1996
8. Tranquillo RT, Murray JD. Mechanistic model of wound contraction. *J Surg Res* 1993;55:233-247
9. Dziedzic D, Orłowski TM, Jakimiuk R. Experimental study of the effects of different stapling devices in healing of the mechanically sutured bronchial stump. *Eur J Cardiothorac Surg* 2000;17:111-116.
10. Moritz A, Grimm M, Eybl E, Grabenwoger M, Grabenwoger F, Bock P, Wolner E. Improved spontaneous endothelialization by postfixation treatment of bovine pericardium. *Eur. J. Cardiothorac. Surg.* 1991;5:155-160.
11. Vaughn CC, Vaughn PL, Vaughn CCIII, Sawyer P, Manning M, Anderson D, Roseman L, Herbst TJ. Tissue response to biomaterials used for staple-line reinforcement in lung resection: A comparison between expanded polytetrafluoroethylene and bovine pericardium. *Eur J Cardiothorac Surg* 1998;13:259-265.
12. Simionescu D, Simionescu A, Deac R. Detection of remnant proteolytic activities in unimplanted glutaraldehyde-treated bovine pericardium and explanted cardiac bioprostheses. *J Biomed Mater Res.* 1993;27:821-829.
13. Jorge-Herrero E, Fernández P, Gutiérrez M, Castillo-Olivares JL. Study of the calcification of bovine pericardium: analysis of the implication of lipids and proteoglycans. *Biomaterials.* 1992;12:683-689.
14. Weder W, Inci I, Korom S, Kestenholz PB, Hillinger S, Eich C, Irani S, Lardinois D. Airway complications after lung transplantation: risk factors, prevention and outcome. *Eur J Cardiothorac Surg.* 2009;35:293-298.