

# Expression of Cyclin D1 in Oral Leukoplakia Compared with Normal Mucosa, Benign and Malignant Tumors of the Oral Cavity

Bögözi B<sup>1</sup>, Mezei T<sup>2</sup>, Bocskay I<sup>3</sup>

<sup>1</sup> Department of Oral and Maxillofacial Surgery, Faculty of Dental Medicine, University of Medicine and Pharmacy, Târgu Mureș, Romania

<sup>2</sup> Department of Pathology, Faculty of General Medicine, University of Medicine and Pharmacy, Târgu Mureș, Romania

<sup>3</sup> Consultant Professor, Faculty of Dental Medicine, University of Medicine and Pharmacy, Târgu Mureș, Romania

**Introduction:** Cyclin D1 is a rate-limiting controller of the G1 phase and the G1 to S transition of the cell cycle. It's overexpression may cause disturbance in the normal cell cycle, which may lead to an increased proliferation and consecutive tumour formation. Our objective was to analyse the expression of Cyclin D1 in oral leukoplakia – the most frequent potentially malignant disorder of the oral mucosa – in comparison with normal mucosa, benign and malignant tumours of the oral cavity.

**Material and methods:** For this paper 51 consecutive cases of oral leukoplakia – surgically treated at the Oro-Maxillo-Facial Surgery Clinic from Târgu Mureș – and, for comparison 9 benign tumours and 27 oral squamous cell carcinomas (OSCCs) were selected. Eight normal mucosa samples were obtained from the peripheral regions of the benign tumours, excized with safe surgical margins. Histopathologically leukoplakias were graded as: with no, mild, moderate or severe dysplasia (G0-3), and OSCCs as: well-, moderately- or poorly-differentiated (G1-3). After immunohistochemical staining for Cyclin D1, statistical analysis was performed regarding the expression of the studied marker.

**Results and conclusions:** In our findings the difference between the expression of Cyclin D1 in normal mucosa, benign tumours and leukoplakias with no dysplasia was not significant, but the expression of this marker increased significantly with the increase of the grade of dysplasia in case of leukoplakias. A statistically significant difference was found also between leukoplakias and OSCCs, without any correlation regarding the histopathological grade of OSCCs.

**Keywords:** Cyclin D1, immunohistochemistry, oral leukoplakia, oral cancer

Received: 16 August 2012 / Accepted: 2 October 2012

## Introduction

The development of malignant tumours of the oral cavity is a complex, multistage process in which the premalignant disorders play an important role. Some authors distinguish two basic steps in this process: first the transformation of normal mucosa into a potentially malignant lesion or condition, and secondary the evolution of these lesions towards oral squamous cell carcinomas (OSCCs) [1,2]. However, it is known that an OSCC can develop directly from normal oral mucosa and also that in some cases premalignant lesions – even those with high risk – do not evolve towards malignant transformation.

In a recently held WHO workshop it has been recommended the use of the term "potentially malignant disorders" instead of "potentially malignant lesions" or "conditions", the most frequent of these – representing about 85% – being oral leukoplakia. The average malignant transformation rate is about 4%, but it varies between 0.1–28% according to different studies. Despite of big progresses achieved in molecular biology and immunohistochemistry, in the present there is no single reliable marker to predict this transformation [3,4].

The complex process of carcinogenesis involves a series of mutations of multiple genes, some of them with important role in the cell cycle control. Cyclin D1, a 45kD protein encoded by the Cyclin D1 gene (located on chro-

mosome 11q13) is one of them. It is a rate-limiting controller of the G1 phase and the G1 to S transition of the cell cycle. It's overexpression may cause disturbance in the normal cell cycle, leading to a shortened G1 phase, which may cause an increased proliferation and consecutive tumour formation [5–8].

The expression of Cyclin D1 was studied separately in normal oral mucosa, potentially malignant disorders and carcinomas, or some authors compared two of these categories. Some of the studies also tried to correlate this expression with histopathological grading or with different clinical features such as gender, age, localization, smoking habits etc., but the reported results were not conclusive, sometimes even contradictory [5–11].

Hence our objective was to analyse the expression of Cyclin D1 in oral leukoplakia in comparison with normal mucosa, benign and malignant tumours of the oral cavity, also considering clinical and histopathological aspects.

## Materials and methods

### Study subjects

For this study tissue samples (incisional or excisional biopsies) from 51 cases of oral leukoplakia (24 males and 29 females, mean age 56.88 years), 9 benign tumours (4 males and 5 females, mean age 54.89 years) and 27 oral squamous cell carcinomas (OSCCs) (21 males and 6 females, mean age 64.81 years) – treated at the Oro-Maxillo-Facial Surgery Clinic from Târgu Mureș between 2006–2010 –

were used. Eight normal mucosa samples (4 males and 4 females, mean age 56.62 years) were obtained from the peripheral regions of the benign tumours, excised with safe surgical margins. The tissue samples were embedded in paraffin and then 3–5  $\mu\text{m}$  thick sections were cut, 2 for each case (one for haematoxylin and eosin (H&E) and one for the immunohistochemical (IHC) staining for Cyclin D1).

The H&E stained sections were used for the histopathological grading of leukoplakias and OSCCs, according to the World Health Organization criteria for typing cancers and pre-cancers of the oral cavity. We have differentiated leukoplakias with no dysplasia (G0, n=27), or – when present – with mild (G1, n=10), moderate (G2, n=7) or severe dysplasia (G3, n=7), and well- (G1, n=8), moderately- (G2, n=9) or poorly-differentiated (G3, n=10) OSCCs [12,13]. Leukoplakias were classified regarding their clinical aspect also, as: homogenous (n=22), verrucosus (n=18) and erythro-leukoplakias (n=11) [14,15]. The benign tumours were represented by fibroma (n=4), fibrolipoma (n=1), epulis (n=2) and hiperplasia (n=2).

### Immunohistochemistry

Immunohistochemical staining was carried out using Monoclonal Rabbit Anti-Human Cyclin D1 Clone SP4 (Dako) as primary antibody, in 1:100 dilution. As negative control we used a slide with exclusion of primary antibody in the IHC staining process and a demonstrated Cyclin D1 positive OSCC case served as a positive control.

### Image acquisition and processing

After immunohistochemical staining digital slides were created by scanning the sections with the Zeiss MiraxScan digital slide acquisition system (Carl Zeiss Jena GmbH, Jena, Germany), controlled by MiraxScan software (3DHitech, Budapest, Hungary) installed on a Fujitsu-Siemens Celsius Workstation computer (4  $\times$  2 GHz CPU, 2 GB RAM). Then we selected 3–5 zones from the lesional area of each specimen and these parts were saved from the digital slides using 3DHitech Panoramic Viewer as separate images (in TIFF format) [16].

### Evaluation of immunohistochemistry and statistical analysis

The expression of Cyclin D1 was quantified by calculating the labelling index (LI) for each case, using the „Cell Counter” tool of the ImageJ software (version 1.46). IHC positive epithelial cells were counted (manually, but assisted by the computer) in each of the TIFF images previously saved, and the mean percentage/case of these positive cells was calculated (LI). The presence of a brown-coloured end product indicates positive immunoreactivity (Figure 1). In our study, cells were considered positive if there was any nuclear staining regardless of the intensity. Finally, the means of LIs for each group of the studied lesions were

compared statistically with GraphPad InStat, using the unpaired t test or when needed (when the differences between the standard deviations of the compared groups was statistically significant) the unpaired t test with Welch correction.

### Results

All normal tissue samples and benign tumours were positive for Cyclin D1. Leukoplakias showed Cyclin D1 expression in 92.16% of the cases (n=47) and 4 specimens (7.84%) were negative, while among the OSCCs 88.89% of the samples (n=24) were positive, and 3 cases (11.11%) were negative for the studied marker. From the 4 negative cases of leukoplakia 2 showed no dysplasia and 2 presented mild dysplasia, and the negative OSCCs was represented by 2 poorly- and 1 moderately-differentiated specimen. Only positive samples were included in the statistical analysis.

We mention here that positive cells are present in the basal and parabasal layers of normal mucosa and low grade leukoplakias (Lp.-D0, D1) and with increasing of the grade of dysplasia they appear in the middle third or even in the superficial layer of the epithelium. In a few cases we also found some cytoplasmatic staining.

The mean labelling indexes for the different categories (and their standard deviations) are presented in Figures 2, 3 and 4.

Figure 2 shows the labelling indexes of histopathological graded leukoplakias and OSCCs, compared with benign tumours and normal mucosa. No statistically significant difference was found between normal mucosa and benign tumours ( $p=0.5625$ ); benign tumours and leukoplakias with no dysplasia (Lp.-G0) ( $p=0.4978$ ) or normal mucosa and Lp.-G0 ( $p=0.2539$ ), but the difference became significant between normal mucosa and leukoplakias with mild dysplasia (Lp.-G1) ( $p=0.0114$ ) and benign tumours and Lp.-G1 ( $p=0.0251$ ). Regarding the different histopathological groups for leukoplakias, the difference between Lp.-G0 and Lp.-G1 was not quite significant ( $p=0.0847$ ), but then increased significantly with the grade of dysplasia (Lp.-G1 vs. Lp.-G2  $p=0.0043$ ; Lp.-G2 vs. Lp.-G3  $p=0.0012$ ). However no statistically significant difference was present regarding the histopathological grades of OSCCs (OSCC-G1 vs. OSCC-G2  $p=0.6747$ ; OSCC-G2 vs. OSCC-G3  $p=0.6625$ ; OSCC-G1 vs. OSCC-G3  $p=0.9371$ ), nor between the group of leukoplakias with severe dysplasia and OSCCs (Lp.-G3 vs. OSCC-G1  $p=0.7120$ ; Lp.-G3 vs. OSCC-G2  $p=0.2805$ ; Lp.-G3 vs. OSCC-G3  $p=0.8390$ ).

In Figure 3 we present the values of labelling indexes for leukoplakias classified from the clinical point of view, and compared with normal mucosa, benign tumours and OSCCs. We found an extremely significant difference between homogenous and verrucosus leukoplakias ( $p<0,001$ ) and significant differences between verrucosus and erythro-leukoplakias ( $p<0.05$ ) and erythro-leukoplakias and OSCCs ( $p<0.05$ ). The difference was not significant when comparing the normal mucosa with homogenous leuko-

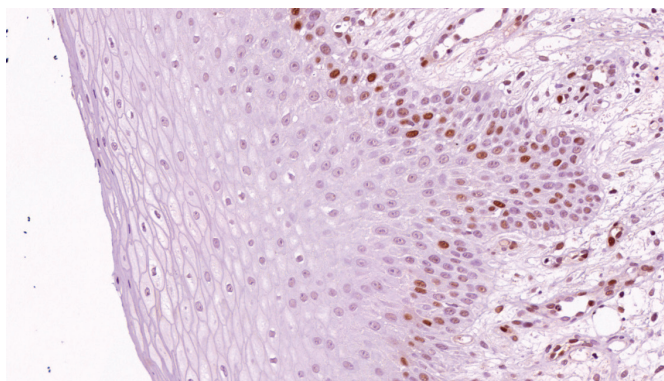


Fig. 1. Cyclin D1 expression in a leukoplakia with no dysplasia (IHC Cyclin D1, Ob. 20x)

plakias ( $p=0.6518$ ) or benign tumours with homogenous leukoplakias ( $p=0.8510$ ).

Figure 4 compares the labelling indexes of the total of leukoplakias with normal mucosa ( $p<0.001$ ), benign tumours ( $p<0.001$ ) and the total of OSCCs ( $p<0.001$ ), the differences being extremely significant in all three cases.

**Discussion**

Cyclin D1 expression was studied in numerous papers in oral lesions, including normal oral mucosa, pre-malignant lesions and OSCCs, comparing both histologically and clinically graded lesions, or other clinical features such as gender, age, anatomical site, tobacco habits, even the impact on survival of cancer patients. However, the results are not consistent and conclusive.

Qualitative expression of Cyclin D1 varies in a wide range according to different authors. Leukoplakias were positive for Cyclin D1 in all the studied cases according to Liu et al. (47 cases) [8] and Kövesi et al. (18 cases) [11], while Raju found positivity in 90% of the cases ( $n=29$ ) [7], compared with 92.16% (51 cases) of our study. However, Mishra found no immunoreactivity for Cyclin D1 in normal mucosa nor in leukoplakias [1]. Positivity in case of OSCCs was found in 31.30% (51 cases) by Mishra et al. [1], 45% (40 cases) by Swati et al. [5], 70.70% (41 cases) by Angadi et al. [10], 73% (111 cases) by Perisanidis et al. [9], 91% (11 cases) by Raju et al. [7]. Our results showed 88.89% (27 cases) of positive specimens.

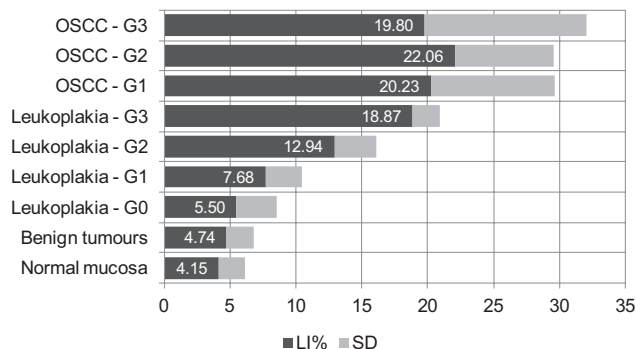


Fig. 2. Labelling indexes (LI) and standard deviations (SD) – histopathological grading of leukoplakias and OSCCs

Regarding the quantitative analysis of expression of Cyclin D1 in leukoplakias, some authors found a statistically significant increase with clinical stage [11], others with the histopathological grade [7,8], our results being in concordance with both of these findings. In OSCCs some studies found a significant increase with the lack of differentiation [1,10]. Other studies did not find any correlation with this aspect [5,9], our results being similar.

We also found – as it is reported in the literature – that in the normal mucosa positive cells are seen only in the germinative layer (basal and parabasal, showing even a higher rate in the parabasal layer) [8]. Leukoplakias with low grade dysplasia show the same expression, while in case of high grade dysplasias positive cells appear in the middle and superficial third of the epithelium [7,8].

These differences between the reported results may be due to the discrepancies in grading systems (criteria for appreciating the grade of dysplasia are still subjective) [12, 13], as well to the differences between the modality of evaluating the expression of markers. Some authors calculated only labelling indexes, others considered also the intensity of the coloration (as mild, moderate and high); some considered as positive only nuclear staining, while others cytoplasmatic coloration also. Vora et al. reported exclusively cytoplasmatic staining [5,7,8]. We considered positive cells with any nuclear staining regardless of the intensity, because – in our opinion – the appreciation of the intensity of the colour is very subjective, being hard to in-

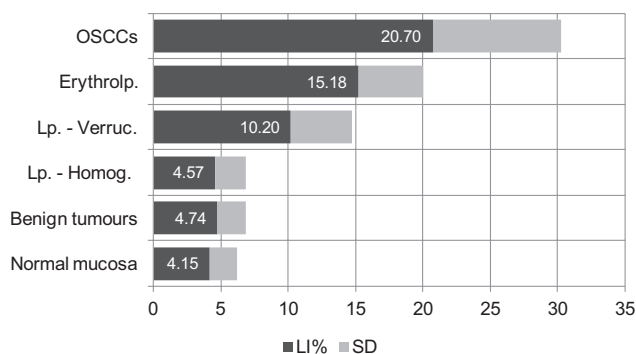


Fig. 3. Labelling indexes (LI) and standard deviations (SD) – clinical grading of leukoplakias

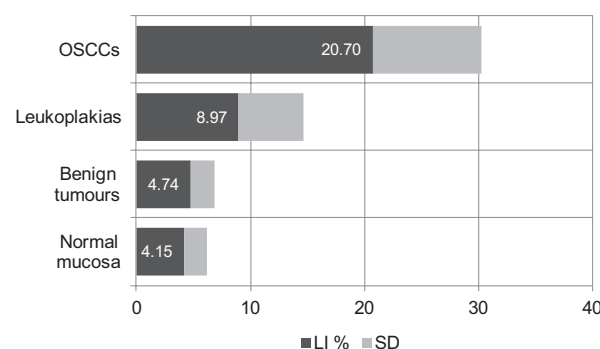


Fig. 4. Labelling indexes (LI) and standard deviations (SD) for the studied categories

clude some cells in the mentioned three categories. As for cytoplasmatic staining, we found it in some rare cases, but in those cells nuclear staining was also present.

## Conclusions

In our findings the difference between the expression of Cyclin D1 in normal mucosa, benign tumours and leukoplakias with no dysplasia was not significant, but the expression of this marker increased significantly with the increase of the grade of dysplasia in case of leukoplakias. A statistically significant difference was found also between leukoplakias and OSCCs, without any correlation regarding the histopathological grade of OSCCs.

Cyclin D1 may have a prognostic value in leukoplakias, but further investigations are needed and correlation with other immunohistochemical markers should be studied.

## References

- Mishra R, Das BR. Cyclin D1 expression and its possible regulation in chewing tobacco mediated oral squamous cell carcinoma progression. *Arch Oral Biol.* 2009;54(10):917-923.
- Napier SS, Speight PM. Natural history of potentially malignant oral lesions and conditions: an overview of the literature. *J Oral Pathol Med.* 2008;1:1-10.
- Ben Slama L. Potentially malignant disorders of the oral mucosa: terminology and classification. *Rev Stomatol Chir Maxillofac.* 2010;111(4):208-212.
- van der Waal I. Potentially malignant disorders of the oral and oropharyngeal mucosa; terminology, classification and present concepts of management. *Oral Oncol.* 2009;45(4-5):317-323.
- Swati S, Madhusudan AS, Nisheeth S, Nidhi D. Cyclin D1 Expression and its Correlation with Histopathological Differentiation in Oral Squamous Cell Carcinoma. *Scientific World Journal.* 2012;2012:978327. Epub 2012 May 2
- Mithani SK, Mydlarz WK, Grumbine FL, Smith IM, Califano JA. Molecular genetics of premalignant oral lesions. *Oral Dis.* 2007;13(2):126-133.
- Raju B, Mehrotra R, Oijordsbakken G, Al-Sharabi AK, Vasstrand EN, Ibrahim SO – Expression of p53, Cyclin D1 and Ki-67 in Pre-malignant and Malignant Oral Lesions: Association with Clinicopathological Parameters. *Anticancer Research.* 2005;25:4699-4706.
- Liu SC, Klein-Szánto AJP. Markers of proliferation in normal and leukoplakic oral epithelia. *Oral Oncol.* 2000;36(2):145-151.
- Perisanidis C, Perisanidis Beata, Wrba F, Brandstetter Anita, et al. Evaluation of immunohistochemical expression of p53, p21, p27, cyclin D1, and Ki67 in oral and oropharyngeal squamous cell carcinoma. *J Oral Pathol MedsZAs.* 2012;41:40-46.
- Angadi PV, Krishnapillai R. Cyclin D1 expression in oral squamous cell carcinoma and verrucous carcinoma: correlation with histological differentiation. *Oral Surg Oral Med Oral Pathol Oral Radiol Endod.* 2007;103(3):30-35.
- Kövesi G, Szende B. Prognostic value of cyclin D1, p27, and p63 in oral leukoplakia. *J Oral Pathol Med.* 2006;35(5):274-277.
- Speight PM. Update on Oral Epithelial Dysplasia and Progression to Cancer. *Head and Neck Pathol.* 2007;1:61-66.
- Bouquot J, Speight PM, Farthing PM. Epithelial Dysplasia of the Oral Mucosa – diagnostic problems and prognostic features. *Current Diagnostic Pathology.* 2006;12:11-22.
- Amagasa T, Yamashiro M, Uzawa N. Oral premalignant lesions: from a clinical perspective. *Int J Clin Oncol.* 2011;16(1):5-14.
- Bucur A, Navarro C, Lowry J, Acero J. *Compendiu de chirurgie oro-maxilo-facială, Vol. II.* Q Med Publishing, București, 2009.
- Mezei T, Szakács M, Dénes L, Jung J, Egyed-Zsigmond I. Semiautomated Image Analysis of High Contrast Tissue Areas Using Hue/Saturation/Brightness Based Color Filtering. *Acta Medica Marisiensis.* 2011;57(6):679-684.