

CASE REPORT

Genetic Investigation and Clinical Aspects in a Romanian Treacher Collins Syndrome Family – A Case Report

Mădălina Anciu^{1*}, Florin Tripon^{2,3}, Carmen Duicu^{1,3}, Carmen Gliga¹, Claudia Bănescu^{1,2,3}

1. Emergency Clinical County Hospital, Targu Mures, Romania

2. Genetics Laboratory, Center for Advanced Medical and Pharmaceutical Research, Targu Mures, Romania

3. George Emil Palade University of Medicine, Pharmacy, Science, and Technology of Targu Mures, Romania

Introduction: In approximately 96% of probands, the diagnosis of Treacher Collins Syndrome (TCS) is confirmed by molecular genetic tests. These tests can detect heterozygous mutation of TCOF1 gene (coding treacle protein) and variants of POLR1D gene (coding RNA polymerase I subunit D) with autosomal dominant inheritance, or biallelic variants of POLR1C gene (coding RNA polymerase I subunit C) and POLR1D with autosomal recessive inheritance. **Case presentation:** We present a neonate proband with family history of clinical features suggestive for TCS. Our patient was investigated for copy number changes (CNCs) of TCOF1 gene using SALSA MLPA P310-B3 TCOF1 probemix to perform Multiplex Ligation-dependent Probe Amplification (MLPA), the results being normal. Dysmorphic features revealed “bird-like” face with trigonocephaly, craniosynostosis, hypoplastic supraorbital rims, underdeveloped zygomas, mandibular hypoplasia and retrognathia (mandibulofacial dysostosis). Other clinical features, like abnormal position and structure of the external ears (microtia, with a bilateral low-set ears, crumpled and malformed pinnae and aural atresia), were also observed. **Conclusion:** Taking into account our results, and also data found in literature, we consider that all TCS cases, but in particular patients with specific TCS features and without CNCs, require additional investigations using sequencing techniques.

Keywords: TCOF1 gene, Treacher Collins syndrome, MLPA technique, neonate

Received 16 August 2019 / Accepted 20 November 2019

Introduction

In 1846, Thomson described for the first time a new syndrome, followed by the work of Berry (1889), Treacher Collins (1900) and completed by Franceschetti and Klein in 1949 [1]. Treacher Collins syndrome (TCS, OMIM 154500), named also Treacher Collins-Franceschetti syndrome or mandibulofacial dysostosis (MFD) arises through a reduction mechanism in the number of cranial neural crest cells given by a haploinsufficiency of the treacle protein. The cells subsequently migrating to the first and second pharyngeal arches [2]. This condition develops between the 20th day and the 12th week of intrauterine life and it is an autosomal dominant disorder of craniofacial development occurring in one in 50,000 live births [3, 4]. Even among members of the same family, signs, symptoms and severity of this disorder can vary greatly from one person to another, differing from almost imperceptible to severe.

In approximately 96% of probands, the diagnosis of TCS is confirmed by molecular genetic tests. These tests can detect heterozygous mutation of TCOF1 gene (coding treacle protein) and variants of POLR1D (coding RNA polymerase I subunit D) with autosomal dominant inheritance, or biallelic variants of POLR1C (coding RNA polymerase I subunit C) and POLR1D with autosomal recessive inheritance. In the remaining 4% of probands, when molecular genetic testing does not detect allelic variants in

either of the known genes, the diagnosis of this condition is established based on clinical findings only [5].

Thus far, *TCOF1* gene is known to be implicated in more than 90% of cases with TCS and approximately 130 distinct mutations including insertion, splicing and non-sense mutations with a distribution along 26 exons located on 5q33.1 locus, have been described in the literature [6, 7]. Moreover, less than 40% of patients have a family history of TCS, while de novo appearance of this condition arises in 60% of the cases [8, 9]. As stated by Mendelian laws of genetics, an affected parent may transmit the pathogenic variant to the offsprings with a risk of 50%, which highlights the importance of genetic counseling in the case of affected individuals and their families [3]. The present report illustrates the clinical findings and molecular analysis of TCS on a neonate with a family history of this condition, without molecular testing being performed on the family members.

Case presentation

We describe the case of a late preterm Caucasian male newborn, small for gestational age who was the product of a primigravid mother and non-consanguineous parents. The pedigree analysis showed a positive family history for congenital bilateral hearing impairment in the maternal lineage, in the first and second degree (Figure 1). The newborn was delivered by Cesarean section (C-section) at only 36 weeks of gestation because of maternal pregnancy-induced hypertension (PIH) and severe preeclampsia. The amniotic

* Correspondence to: Madalina Anciu
E-mail: mada_anciu@yahoo.com

fluid was clear and Apgar scores were 8 at 1 minute and 9 at 5 minutes. Birth weight was 1850 grams (<3th percentile) with a 46 cm length (> 10th centile), 30 cm head circumference (<10th centile) and appropriate postpartum adaptation.

Clinical evaluation of the newborn revealed a “bird-like” face with trigonocephaly, craniosynostosis, hypoplastic supraorbital rims, underdeveloped zygomas, mandibular hypoplasia and retrognathia (mandibulofacial dysostosis). The newborn also presented antimongoloid slant of palpebral fissures, microphthalmia and coloboma, without stenosis or choanal atresia. Other clinical features, like abnormal position and structure of the external ears (microtia with a bilateral low-set ears, crumpled and malformed pinnae and aural atresia), were also observed.

Cranial ultrasonography revealed no additional abnormalities and described structures being in relationship with gestational age. 2D-echocardiography showed ostium secundum atrial septal defect < 3 mm with a septal aneurysm and left-to-right cardiac shunt, but normal cardiac chambers. Ophthalmologic examination highlighted clear and well-defined borders of optic disc with immature retinal vascularization of zone III and a normal macula. Furthermore, a bilateral iris and chorioretinal coloboma on the inferonasal quadrant was observed. Pediatric surgical evaluation confirmed our suspicion of hypospadias, based on the physical exam. In evolution, abdominal ultrasound performed at 4 weeks of life revealed mild bilateral hydronephrosis. Over time, hydronephrosis showed a slight improvement of the grade, at the time of follow-up requiring only ultrasound monitoring. Native computer tomography (CT) of the head was performed, describing the inner ear, as well as the internal auditory canal (IAC) within normal limits. It also described, the presence of tympanic cavity, but with a poor visualization of the bilateral auditory ossicular system and narrowed external auditory canals (EAC). The patient was referred to the medical genetics department where the mother was observed to present similar peculiar facial aspects, but with lower clinical phenotype expression severity. In the upcoming weeks the newborn was feeding well without functional respiratory disorder. He had an adequate evolution and was discharged after the first month of life with medical recommendations.

For genetic analysis, genomic DNA was extracted from venous peripheral blood of the newborn and also from the mother, using PureLink Genomic DNA kit (ThermoFisher, Massachusetts, USA). The study was approved by the Ethics Committee of the University of Medicine and Pharmacy Tîrgu Mureş, Romania (No. 47 from February 23, 2018). Informed written consent for testing and publication was obtained from the parents.

Multiplex Ligation-dependent Probe Amplification (MLPA) analysis was reported as a useful, fast and low-priced method to evidence copy number changes (CNCs) in several genes [10, 11]. On the other hand, several pathogenic CNCs are known to be implicated in TCS. As a result, we performed MLPA analysis using SALSA MLPA P310-B3 *TCOF1* probemix from MRC-Holland (Amsterdam, Netherlands). According to the manufacturer description, the probemix contains one probe for every exon of the *TCOF1* gene, excepting exons 8, 19 and 20. Furthermore, a probe for intron 6 and another one for intron 16 were included in this probemix along with 10 reference probes for different locations on the autosomal chromosomes. Denaturation of DNA, reaction of hybridization and ligation, followed by polymerase chain reaction (PCR) and capillary electrophoresis for fragment separation were performed as previously described, according to the manufacturer instructions [12].

We performed fragment analysis by capillary electrophoresis with 50 cm array and POP-7 polymer, using Applied Biosystems 3500 Genetic Analyzer. Final results were obtained using the Coffalyser.Net software taking into account the normal ratio, for the region of interest, between 0.7 to 1.3.

Prominent TCS clinical findings were noticed, in the proband. In addition, congenital bilateral hearing impairment and craniofacial abnormalities, but with lower clinical severity were discovered in his mother as well. Similar phenotype was also noticed in his grandfather who has been clinically diagnosed with TCS.

In both cases, neonate and mother, the results of MLPA analysis failed to detect the presence of CNCs for *TCOF1* gene, all probes included in the kit being in normal ranges (0.7-1.3).

Discussion

The present case report was designed to illustrate the clinical findings and MLPA analysis of TCS in a neonate proband with a family history of this condition, without molecular testing being performed on the family members.

It is known that more than 60% of TCS cases have no previous family history of this condition and appear as de novo mutations [8, 9]. Discordance between genotype and phenotype has been reported in several studies, although there is no clear mechanism of occurrence [13, 14]. Despite the fact that the penetration of genetic mutations with regard to TCS is considered to be high, the diagnosis of this syndrome may be overlooked due to the phenotypic

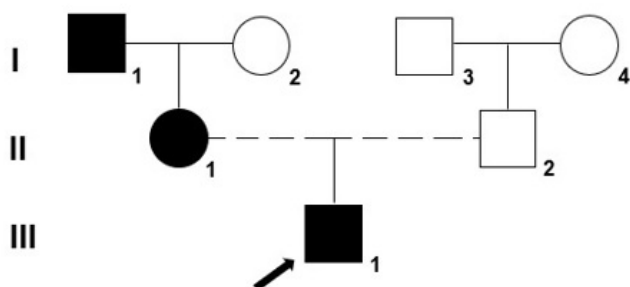


Fig. 1. Pedigree chart of our patient with autosomal dominant inheritance of TCS in the family

variability of clinical manifestations. However, severe cases that can develop respiratory disturbances leading to perinatal mortality have been described [15]. These features highlight the multifactorial nature of this process, with the implication of genetic factors, environmental factors and stochastic events. Taking into account the severity score introduced by Teber et al., based on clinical features, our patient is severely affected scoring 16 out of 20 points [13].

In order to confirm diagnosis and establish the etiology, genetic molecular tests are required to detect possible mutations in the most commonly reported genes involved, such as *TCOF1*, *POLRIC* and *POLRID* genes. Localized on 5q32-q33.1, the *TCOF1* gene was found to be implicated in the development of approximately 90-95% of TCS cases.

In a similar study conducted by Beygo J et al [16] on a cohort of 112 patients investigated with the same technique, MLPA analysis did not confirm the presence of CNCs in the *TCOF1*, *POLRIC* and *POLRID* genes, and revealed only one aberrant signal intensity in exon 3 for one patient. As long as there were not at least two consecutive aberrant signals, based only on MLPA results, it could not be considered a deletion. However, this one aberrant signal suggested the need of targeted additional molecular investigations such as long-range PCR and sequencing technique. Therefore, Beygo J et al were able to identify deletion of the complete sequence of exon 3 with the interest of introns 2 and 3 [16]. For the rest of the patients, where all MLPA probes were in normal ranges, whole gene sequencing was needed. In accordance with our study, Beygo J et al highlights the need for further analysis for point mutations.

A study that focused on phenotypic characteristics and molecular diagnosis using Sanger sequencing of *TCOF1* gene, included a single TCS family. In this research, Han et al [17], identified a heterozygous mutation in exon 3 of the *TCOF1* gene, namely a splice-site c.165-1G> A mutation. The same pathogenic variant was identified in the proband's mother, but not in other relatives, suggesting that a de novo c.165-1G>A mutation may be implicated in the pathogenesis of TCS in this family [17].

A novel 1-bp duplication and a 4-bp deletion identified in the *TCOF1* gene were reported by Caluseriu et al, as further possible pathogenic mechanisms for TCS [18]. Moreover, in the study performed by Vincent et al [19] on 146 subjects with TCS, 63% of patients presented a mutation in the *TCOF1* gene. In 6% of cases, they identified a pathogenic variant of the *POLRID*, but not of the *POLRIC* gene. In addition, in the same study, among patients with clinical features like microcephaly or intellectual disability, they identified one case with a 5q32 deletion. The deleted sequence included calcium/calmodulin dependent protein kinase II alpha (*CAMK2A*) and *TCOF1* genes. They also identified 4 cases carrying a mutation in Elongation Factor Tu GTP Binding Domain Containing 2 (*EFTUD2*) gene [19]. It has been reported that mutations in the *TCOF1*

gene might be responsible for clinical aspects of TCS, as well as mutations in the *CAMK2A* gene for intellectual disability seen in this condition [20]. Genetic analysis of the beforementioned genes was performed by Vincent et al. using the same method as in our present study, and subsequently applying Sanger sequencing method and array-comparative genomic hybridization.

Other two studies [21, 14] including five patients with minimal diagnostic criteria (a newborn and four cases with Turkish origin) and presenting similar clinical features as our patient, described a pathogenic heterozygous deletion in exon 7, c.1021_1022delAG of *TCOF1* gene, using Sanger sequencing [21, 14].

Given the variable expressivity of the clinical symptoms of this syndrome, identifying the causative factors by using a targeted molecular pathway is important for genetic counseling, and treatment strategies of the patient. In our case, the diagnosis of TCS was established based on clinical features of the proband, of his mother and grandfather. Due to the fact that there are several challenges and limitations of molecular analysis in developing countries such as Romania, especially regarding costs, we were unable to sequence the abovementioned genes. Another limitation of our study is the lack of a sample from the grandfather, and the fact that we were unable to investigate the *POLRIC* or *POLRID* genes (although they can account for up to 5% of TCS cases).

In conclusion, taking into account our results, and also data found in literature, we consider that all TCS cases, but in particular patients with specific TCS features and without CNCs, require additional investigations using sequencing techniques.

Conflict of interest

None to declare.

References

1. Renju R, Varma BR, Kumar SJ, Kumaran P. Mandibulofacial dysostosis (Treacher Collins syndrome): A case report and review of literature. *Contemp Clin Dent*. 2014;5:532-534
2. Kasat V, Baldawa R. Treacher Collins syndrome - A case report and review of literature. *J Clin Exp Dent*. 2011;3:e395-399
3. Mohan RPS, Verma S, Agarwal N, Singh U. Treacher Collins syndrome: A case report. *BMJ Case Rep*. 2013;2013:bcr2013009341
4. Panta P, Yaga US, Mengji AK, Radhika B, Rao MS. Treacher Collins syndrome - Case report and review. *Oral Health Dent Manag*. 2017;6:955-957.
5. Katsanis SH, Jabs EW. Treacher Collins Syndrome, in: Adam MP, Ardinger HH, Pagon RA, et al., editors. *GeneReviews®* [Internet]. Seattle (WA): University of Washington, Seattle, 2004 [updated 2018], 1993-2019
6. Weiner AM, Scamporrì NL, Calcaterra NB. Fishing the molecular bases of Treacher Collins syndrome. *PLoS One*. 2012;7:e29574
7. Dixon J, Trainor P, Dixon MJ. Treacher Collins syndrome. *Orthod Craniofac Res*. 2007;10:88-95
8. Kumar T, Puri G, Konidena A, Arora N. Treacher Collins syndrome: A case report and review of literature. *J Indian Acad Oral Med Radiol*. 2015;27:488-491
9. Conte C, D'Apice MR, Rinaldi F, Gambardella S, Sangiuolo F, Novelli G. Novel mutations of *TCOF1* gene in European patients with Treacher Collins syndrome. *BMC Med Genet*. 2011;12:125
10. Crauciuc GA, Tripon F, Bogliș A, Făgărășan A, Bănescu C. Multiplex ligation dependent probe amplification - A useful, fast and cost-effective

- method for identification of small supernumerary marker chromosome in children with developmental delay and congenital heart defect. *Rev Romana Med Lab.* 2018;26:461-470
11. Bogliş A, Tripon F, Bănescu C. The utility of molecular genetic techniques in craniosynostosis cases associated with intellectual disability. *Rev Romana Med Lab.* 2018;26:471-477
 12. Bănescu C. Do we really need genetic tests in current clinical practice? *Rev Romana Med Lab.* 2019;27:9-14
 13. Teber OA, Gillessen-Kaesbach G, Fischer S, et al. Genotyping in 46 patients with tentative diagnosis of Treacher Collins syndrome revealed unexpected phenotypic variation. *Eur J Hum Genet.* 2004;12:879-890
 14. Schlump JU, Stein A, Hehr U, et al. Treacher Collins syndrome: clinical implications for the paediatrician--a new mutation in a severely affected newborn and comparison with three further patients with the same mutation, and review of the literature. *Eur J Pediatr.* 2012; 171:1611-1618
 15. Horiuchi K, Ariga T, Fujioka H, et al. Mutational analysis of the TCOF1 gene in 11 Japanese patients with Treacher Collins Syndrome and mechanism of mutagenesis. *Am J Med Genet A.* 2005; 134:363-367
 16. Beygo J, K. Buiting, S. Seland, et al. First Report of a Single Exon Deletion in *TCOF1* Causing Treacher Collins Syndrome. *Mol Syndromol.* 2012;2:53-59
 17. Yan Z, Lu Y, Wang Y, et al. Identification of a novel TCOF1 mutation in a Chinese family with Treacher Collins syndrome. *Exp Ther Med.* 2018;16:2645-2650
 18. Caluseriu O, Lowry BR, McLeod R, et al. The Hutterite variant of Treacher Collins syndrome: a 28-year-old story solved. *Am. J. Med. Genet.* 2013;161A:2855-2859
 19. Vincent M, Genevieve D, Ostertag A, et al. Treacher Collins syndrome: a clinical and molecular study based on a large series of patients. *Genet. Med.* 2016;18:49-56
 20. Vincent M, Collet C, Verloes A, et al. Large deletions encompassing the TCOF1 and CAMK2A genes are responsible for Treacher Collins syndrome with intellectual disability. *Eur J Hum Genet.* 2014;22:52-56
 21. Ulusal S, Gürkan H, Vatansver U, Kürkçü K, Tozkir H, Acunaş B. A case of treachercollins syndrome. *Balkan J Med Genet.* 2013;16:77-80