

CASE REPORT

Prenatal Diagnosis of Binder Phenotype, Naso-Maxillar Hypoplasia

Lucian Gheorghe Pop^{1*}, Ioan Dumitru Suci², Nicolae Bacalbasa³, Oana Daniela Toader^{1,3}

1. National Institute of Mother and Child Care Alessandrescu-Rusescu, Bucharest, Romania

2. Floreasca Emergency Hospital, General Surgery Department, Bucharest, Romania

3. University of Medicine and Pharmacy-Carol Davila-, Bucharest, Romania

4. University of Medicine and Pharmacy -Carol Davila-, Bucharest, Romania

Facial dysmorphism is a common diagnosis which represents a broad spectrum of aetiologies with different outcomes spreading from normal outcome to foetal demise or new-borns with multiple malformations. Prenatal diagnosis can be difficult, making counselling a challenging task even in experienced hands. This paper aims to present an unusual case of facial dysmorphism (Binder phenotype) which resulted in a normal pregnancy. However, throughout the pregnancy, future parents experienced excruciating anxiety, which required multiple prenatal counselling appointments. We believe that in case of a Binder phenotype, genetic testing, multiple scanning appointments and extensive discussion with future parents are vital in the prevention of an unneeded ending of a pregnancy.

Keywords: Binder syndrome, facial anomalies, hypermetropia, anomaly scan

Received 31 May 2020 / Accepted 4 November 2020

Introduction

More than 2500 dysmorphic malformation syndromes have been described. Many of these cases present facial features, which are keystones in the identification and appropriate counselling of the parents. Binder condition, is mainly characterised by naso-maxillar dysplasia which combines midface hypoplasia with the absence of spina nasalis, short columella, leading to facial dysmorphism. Binder syndrome is rather a composite phenotype rather than a single entity. Aetiology of this syndrome is unknown. Different heterogeneous conditions, like systemic lupus erythematosus, chondrodysplasia punctata (CDP, Keutel syndrome, maternal intake of coumarin-based anticoagulants during pregnancy might be involved in causing It is difficult to know the true incidence of Binder syndrome as mild cases are not noticed, but is believed that equally affects both genders (2) and is around 1/18000[1]

Case report

We present a case of a 39 years old patient, multipara, who underwent the anomaly scan at 21 weeks. She had a previous spontaneous vaginal delivery 17 years ago and a normal cfDNA test performed in the first trimester. During the examination, verticalisation of the profile and mild hypermetropia was noted, with the rest of anomaly scan within normal limits. 3D pictures performed at the time of examination confirmed findings and added extra information allowing a proper discussion with future parents. The

facial findings were confirmed using a Samsung WS 80A Elite system (Samsung Medison Co. Ltd., Seoul, Republic of Korea). Findings mentioned above were consistent with a suspicion of Binder syndrome. Following counselling, the parents opted for the invasive procedure, and amniocentesis with subsequent SNP microarray showed normal results. Subsequent growth scans were performed at 28, 32, and 36 weeks accompanied by psychological counselling sessions as per parents' anxiety. The patient had a vaginal delivery at 39 weeks of gestation G-3450 g, Apgar score-9. Further neonatal and pediatric examination showed a healthy baby and his neurodevelopmental chart at 18 months shows a normal behaviour.

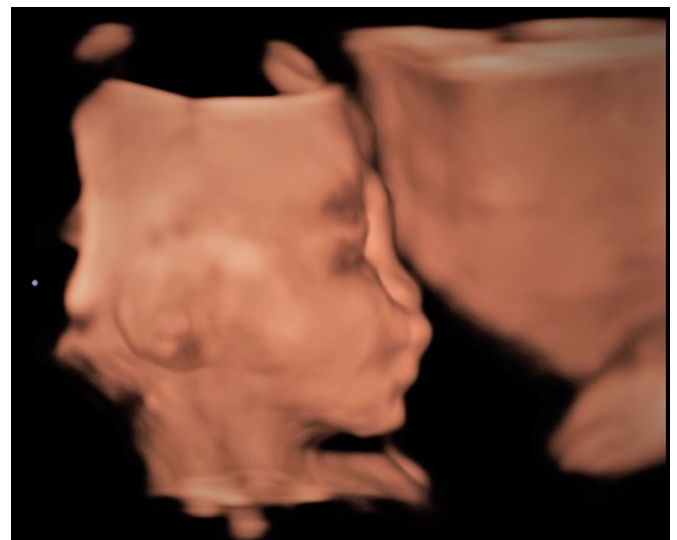

Fig. 1. Binder syndrome, 3D rendering Profile

* Correspondence to: Lucian Gheorghe Pop
E-mail: popluciangh@icloud.com

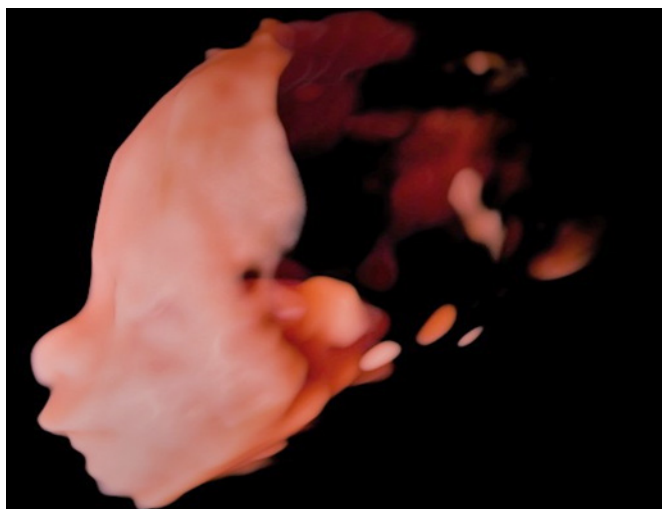


Fig. 2. Normal 3D rendering Profile

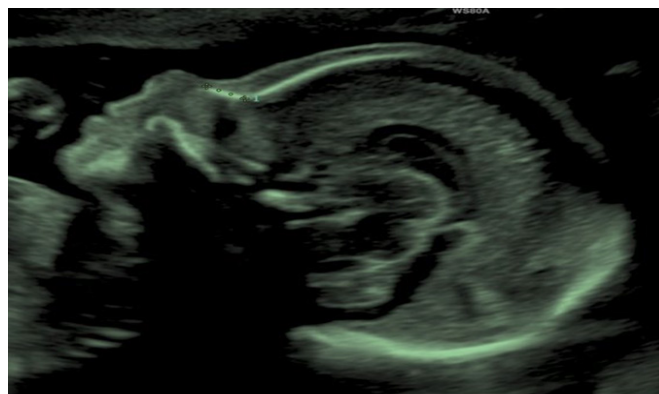


Fig. 5. Normal 2D profile (sharp angle)

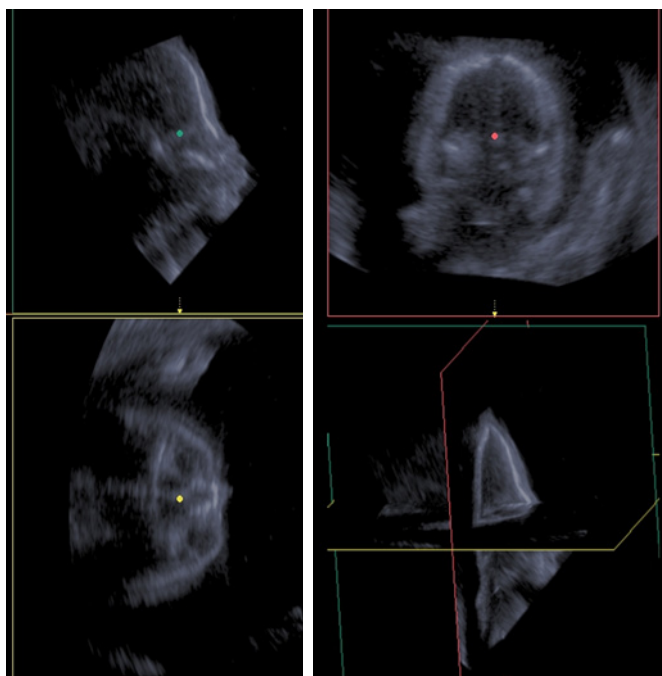


Fig. 3. D Multiplanar view –Binder syndrome wide-angle profile section

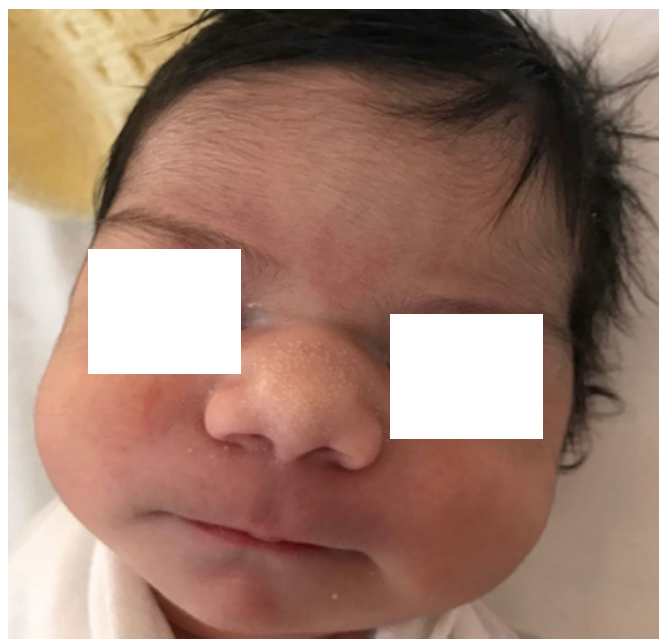

Fig. 6. New-born hypermetropia

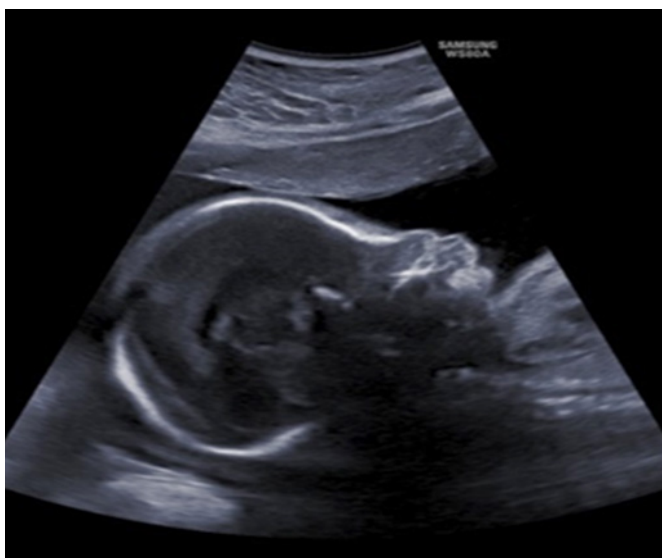

Fig. 4. 2D Binder syndrome, nasal hypoplasia, wide-angle

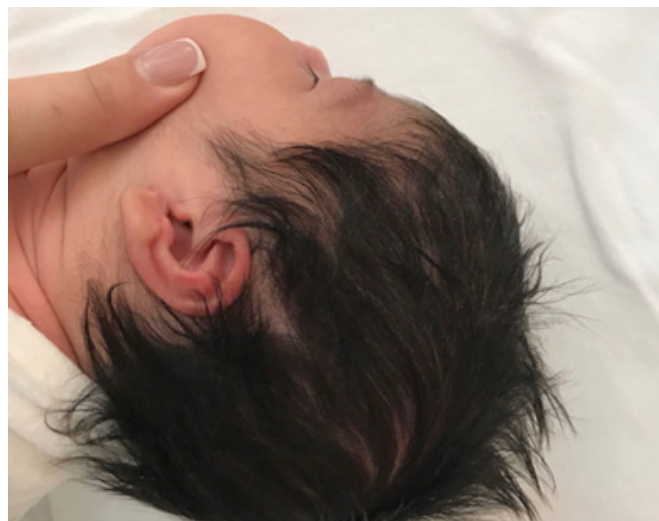

Fig. 7. New-born profile

Discussion

Binder syndrome was first diagnosed in 2000 and encompasses verticalisation of nasal bone, short columella, flattened nose and frequently associated with prognathism of the mandible[2]. The length of the nasal bone is usually normal. The facial anomalies can be isolated or associated with other features, commonly skeletal abnormalities such

as stippled epiphysis, rhizomelic shortening and cervical defects. Strabismus, hearing deficiency, microdontia of the upper incisors can appear later in life. Diagnosis is usually made on ultrasound scan, sagittal section. A careful evaluation of fetal anatomy should be undertaken, especially skeletal and heart assessment [3, 4]. Three-dimensional images help evaluate the face and diagnose Binder syndrome. MRI would bring additional information in cases of skeletal defects. Cases of Binder phenotype with prenatal suspicion of vertebral stenosis or cervicothoracic kyphosis on the antenatal US and Magnetic resonance imaging (MRI), have been described as part of chondroplasia punctata (CP) which is the principal differential diagnosis. Radiographic findings of cartilaginous stippling due to due to calcium build-up during endochondral bone development are the central clue for chondroplasia punctata diagnosis [5]. There are several ways of CP inheritance in an autosomal dominant manner, X linked dominant, and X linked recessive [6]. Imaging diagnosis of Binder syndrome should lead to a detailed review of antenatal and pre-pregnancy history, conditions associated with decreased levels of Vit K, such as hepatic disease, alcoholism, hyperemesis gravidarum [7]. More than 50 conditions associated with low flat nasal bones have been described although, most of them have other associated anomalies. Among genetic conditions that have a flat profile apart chondrodysplasia punctata are Wolff- Hirschhorn syndrome (Greek warrior helmet), Keutel and Robinow syndrome craniosynostosis and fetal warfarin disorder [4, 7-9] (table I).

Introduction of non-invasive prenatal testing (NIPT) in clinical practice has widened screening possibilities advocating that cell-free DNA (cf DNA), in many cases, is a replacement of invasive techniques [7]. Our example demonstrates the limited contribution of NIPT and the further need for invasive procedures both for diagnostic purposes and for ruling out any suspicion of chromosomal abnormalities providing reassurance to patients [10]. While Binder condition in the first trimester has not yet been described, we further enhanced the need of first and second-trimester fetal anomaly scan. Perinatal respiratory problems have been reported in fetuses with spine and cervical abnormalities. An article published by Blumfield at all reports three cases of babies with respiratory distress post-delivery, which should not be surprising as there are spinal, neck and head abnormalities [11]. Nevertheless, when isolated Binder syndrome has an excellent prognosis, with teenagers seeking medical assistance rather for cosmetic reasons.

Conclusions

As is shown, Binder phenotype is a feature of multiple and various conditions. The genetic transmission of Binder syndrome has not been fully elucidated, sporadic cases of recessive, dominant and X linked transmission have been reported [9]. Diagnosis of Binder condition is a large one, encompassing several possibilities which bring emotional

Table I. Differential diagnosis in Binder syndrome

Syndromes	Common facial features	Common ultrasound features	Genetic transmission
Binder	Flat nose, flat face, hypertelorism		Autosomal recessive
Wolff-Hirschhorn	Hypertelorism, micrognathia, short philtrum	Greek warrior helmet	De novo
Chondroplasia-punctata	Nasal hypoplasia	Ephysial stippling, shortening of the limb	X linked dominant X linked recessive Autosomal dominant
Keutel syndrome	N/A	Calcification, ossification in external ears, nose, larynx, epiglottis	Autosomal recessive
Robinow syndrome	Flat face hypertelorism	Macrocephaly, clinodactily, short arms	Autosomal dominant
Crouzon syndrom	Fronto-nasal dysplasia	Flat nose, short fronto-occipital diameter	Autosomal dominant
Fetal warfarin syndrome	Flat face	Stippling	Teratogen

uncertainty for future parents. The phenotype is usually diagnosed through ultrasound imaging. Nevertheless, complementary analyses, MRI, blood tests for hepatic conditions, Vit K deficiency and invasive testing are recommended as a normal result could provide reassurance. Regarding the management of pregnancy with Binder condition, standard obstetric care is recommended with the caveat that delivery should take place in a tertiary centre and neonatal healthcare providers have to be informed of diagnoses as possible respiratory complications are challenging to foresee. Genetic and antenatal counselling is never easy. It requires competent communication skills, strong knowledge of the topic and support among all parties. Technical advances in imaging technology, in genetics in the prenatal field, have brought us tremendous advances. Still, it makes our work more complicated and time-consuming in term of counselling, which is fundamental in support of a meaningful decision.

Authors' contributions

L.P Conceptualisation and writing
 N.B Resources
 I.S. Editing pictures
 O.T. Review

Conflict of interest

None to declare.

References

1. Keppler-Noreuil, K.M. and T.J. Wenzel, Binder phenotype: associated findings and etiologic mechanisms. *J Craniofac Surg*, 2010. 21(5): p. 1339-45.
2. Cook, K., et al., The prenatal diagnosis of Binder syndrome before 24 weeks of gestation: case report. *Ultrasound Obstet Gynecol*, 2000. 16(6): p. 578-81.
3. Bronshtein, M., et al., Prenatal sonographic diagnosis of nasal

- malformations. *Prenat Diagn*, 1998. 18(5): p. 447-54.
4. Alessandri, J.L., D. Ramful, and F. Cuillier, Binder phenotype and brachytelephalangic chondrodysplasia punctata secondary to maternal vitamin K deficiency. *Clin Dysmorphol*, 2010. 19(2): p. 85-7.
 5. Katsube, M., et al., Quantitation of nasal development in the early prenatal period using geometric morphometrics and MRI: a new insight into the critical period of Binder phenotype. *Prenat Diagn*, 2017. 37(9): p. 907-915.
 6. Boulet, S., et al., Brachytelephalangic chondrodysplasia punctata: prenatal diagnosis and postnatal outcome. *Fetal Diagn Ther*, 2010. 28(3): p. 186-90.
 7. Quarrell, O.W., M. Koch, and H.E. Hughes, Maxillo nasal dysplasia (Binder's syndrome). *J Med Genet*, 1990. 27(6): p. 384-7.
 8. Nicolaides, K., et al., Ultrasonographically detectable markers of fetal chromosomal defects. *Ultrasound Obstet Gynecol*, 1993. 3(1): p. 56-69.
 9. Sheffield LJ, Halliday JL, Jensen F. Maxillo nasal dysplasia (Binder's syndrome) and chondrodysplasia punctata. *J Med Genet*. 1991;28(7):503-4.
 10. Suciul I, Galeva S, Abdel Azim S, Pop L, Toader O. First-trimester screening-biomarkers and cell-free DNA. *J Matern Fetal Neonatal Med*. 2019:1-7.
 11. Blumenfeld YJ, Davis AS, Hintz SR, Milan K, Messner AH, Barth RA, et al. Prenatally Diagnosed Cases of Binder Phenotype Complicated by Respiratory Distress in the Immediate Postnatal Period. *J Ultrasound Med*. 2016;35(6):1353-8.