

CASE REPORT

Postpartum pancreatitis in young female – a rare case in the Emergency Department

Adrienn Nemeth^{1,2*}, Puiu Popescu²

1. George Emil Palade University of Medicine, Pharmacy, Science, and Technology of Targu Mures, Romania

2. Emergency Department, Emergency County Hospital, Targu Mures, Romania

Introduction: Acute pancreatitis is a condition that leads to multiple organ failure syndromes if not diagnosed and treated correctly. The most frequent causes of acute pancreatitis are gallstones, alcohol consumption, and elevated triglyceride serum level. **Case Presentation:** A 21-year-old female presented to the emergency department with epigastric pain, nausea, vomiting, and diaphoresis. The patient had a non-complicated vaginal birth four months prior, had no personal history of illness, reported no alcohol consumption, and had a slender body constitution. Laboratory tests outlined a white blood cell count of 22.000/ μ L, elevated neutrophil count, lactate dehydrogenase 294 U/L, and lipemic serum sample reported for chemistry laboratory test. In addition, the contrast-enhanced computed tomography scan revealed severe pancreatitis, with an intraabdominal fluid collection. **Conclusions:** This case report highlights the importance of correct early diagnosis in the postpartum and late postpartum period and raises awareness concerning the possibility of acute pancreatitis in a postpartum woman even if she does not have the two most common risk factors: gallstones or alcohol consumption.

Keywords: acute pancreatitis, postpartum, abdominal pain, hypertriglyceridemia

Received 26 April 2022 / Accepted 30 August 2022

Introduction

Acute pancreatitis is the inflammation of pancreatic tissue, more frequently caused by bile duct obstruction with gallbladder stones or chronic alcohol consumption. The third risk factor is serum triglyceride levels above 1000 mg/dl. In pregnant women, serum triglyceride level often rises above 300mg/dl, with a peak in the last trimester [6]. The postpartum period exposes women to further diseases and conditions. We report a case of acute pancreatitis in a young woman in the late postpartum period caused by hypertriglyceridemia.

Methods

This case report follows the principles outlined in the WMA statement of ethical principles for medical research. The patient signed a written informed consent at the time of admission that all information regarding her health condition would be used in scientific research under the protection of anonymity.

Case Presentation

A woman, age 21, presents at night in the Emergency Department with gastrointestinal complaints: epigastric pain irradiating in the lower abdomen and back, nausea, vomiting, loss of appetite, and diaphoresis, starting a few hours before admission. The patient had a non-complicated vaginal birth four months prior, had no personal history of illness, and reported no smoking, alcohol, or drug consumption. In addition, she denied consumption of fatty food and any abnormal dietary behavior as she was breastfeeding.

Physical examination showed a slender build, a slightly underweight body mass index – 18.3 kg/m² (48 kg, 162 cm), pale and sweaty skin, cardiac frequency 102/min, blood pressure 98/65 mmHg, oxygen saturation level SO₂ = 98%, body temperature 38.3°C. The pulse and heart sounds were regular, tachycardic, the thorax evenly expanding, and normal lung sounds.

The abdomen was tender and painful over the epigastrium, left, and right hypochondriac, and lumbar areas, with bowel sounds present. The stool and urine output during the day was without changes.

Laboratory and paraclinical investigations

ECG displayed sinus rhythm with a high heart rate of 102 bpm, intermediate QRS axis. Covid-19 Antigen Test was negative.

Blood laboratory tests presented a pH of 7.33, elevated Lactate and C reactive Protein levels, and low sodium and serum calcium. Complete Blood Count showed high leucocyte count with 85% neutrophils, red blood cells, and platelets within normal range (Table I).

The Emergency Laboratory requested another blood sample because chemistry, liver panel, amylase, and serum triglyceride level were impossible to determine due to the lipemic blood sample (Figure 1).

Table I. Blood laboratory tests results

Variable	Results
White blood cells	22.18*10 ³ / μ L
Red blood cells	4.79*10 ³ / μ L
Platelets	322.00*10 ³ / μ L
International Normalized Ratio -INR	1.40
Lactate	3.6 mmol/L
C Reactive Protein	>180g/L
Serum Calcium Ca ²⁺	6.4 mg/dl
Serum Sodium Na ⁺	126 mmol/L

* Correspondence to: Adrienn Nemeth
E-mail: nemeth_adrienn@yahoo.com

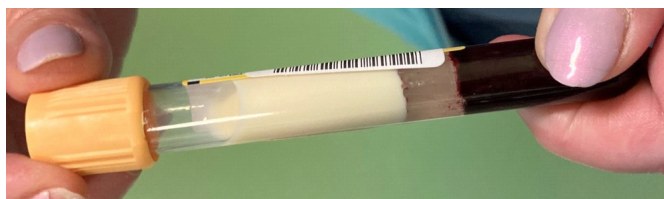

Fig. 1. Picture of intense lipemic serum, 21 years old female

Symptomatic treatment was administered: painkillers, spasmolytic medicine, and hydration with Ringer’s solution. Pain turned so intense that the patient needed administration of 50 µg opioid drug twice since admission. After having the laboratory tests and imaging, empirical intravenous antibiotic treatment with 1 gram of Ceftriaxone was initiated.

Meanwhile, the patient underwent a contrast-enhanced computed tomography scan that revealed diffuse enlargement of the pancreas and blurring of peripancreatic fat planes. There was also a filling defect in the body and tail of the pancreas. The spleen and liver both appeared enlarged. A moderate quantity of intraperitoneal fluid was described (Figures 2-4).

The second chemistry sample outlined a triglyceride level of 5010 mg/dl, amylase 1984 U/L, alanine aminotransferase ALT 130 U/L, and aspartate aminotransferase AST 189 U/L.

The patient was successfully admitted to the gastroenterology department and discharged four weeks later with an improved general state and laboratory tests under conservative treatment.

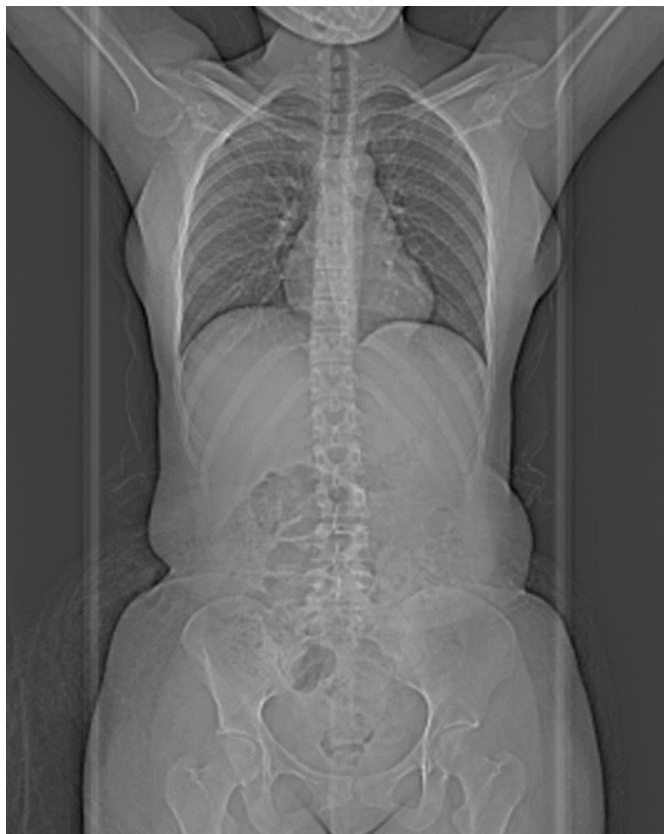

Fig. 2. CT scan of patient – notice her slender build

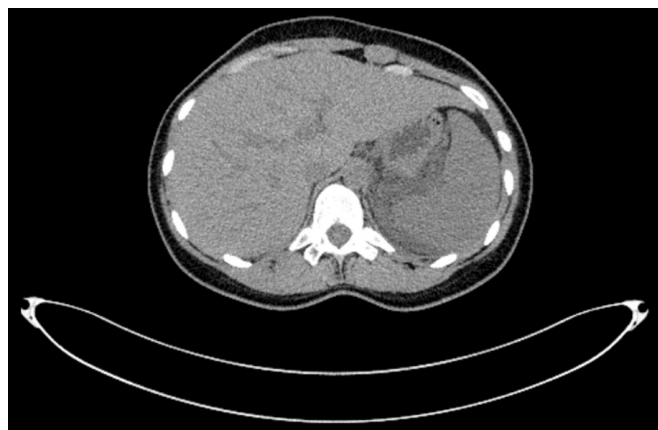


Fig. 3. CT scan with the liver and the spleen; both appear enlarged and the medial part of the spleen is in contact with pancreatic inflammatory tissue.

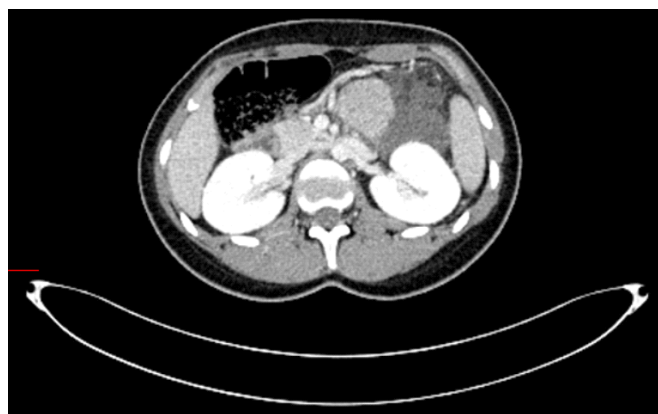

Fig. 4. Body and tail of pancreas are inhomogeneous, also there is intraabdominal fluid, and areas of necrosis.

Discussion

Pancreatitis is caused by inflammation of the pancreatic tissue due to gallbladder stones and alcohol consumption. Rarely, it is caused by elevated serum calcium levels, adverse effects of estrogens, progesterone, immunosuppressants, some diuretics, severe abdominal trauma, viral infections, autoimmune disorders, and accidental lesion of the pancreas during surgery.

The postpartum period can present a high risk for developing several life-threatening conditions, such as HELLP syndrome and deep venous thrombosis. Acute pancreatitis in pregnancy and postpartum is a topic that has recently been reviewed and studied [7] due to the increasing number of reported cases [3,4,5,6]. Pancreatitis in pregnancy is caused by hormonal changes due to peaking estrogen and progesterone levels that influence lipid metabolism. The leading cause of pancreatitis is gallstones due to increased cholesterol secretion in the third trimester and progesterone-induced stasis in the gallbladder and Oddi sphincter. The second reported cause is a high level of triglycerides, which usually stabilizes around 350 mg/dl in pregnant women. Exceptionally it can exceed 1000 mg/dl and can cause pancreatic inflammation. Alcohol and drug-induced pancreatitis are rare in this category of patients.

Maringhini et al. identified gallstones as the predominant cause of acute pancreatitis in younger women; how-

ever, several case reports plead for hypertriglyceridemia in pregnant women without non-gestational hyperlipidemia, similar to the case presented. Another case reported in Chile [1] identified a parathyroid nodule as the cause of hypercalcemia in a woman 32 weeks into gestation with acute pancreatitis, a very rare situation (0.15%). The patient underwent surgical treatment with removal of parathyroid nodule after conservative treatment of gastrointestinal disease.

In the postpartum period, the hormonal changes have not been remitted yet, and several cases of postpartum idiopathic pancreatitis with hypertriglyceridemia are reported.

The diagnostic approach for acute abdominal pain included laboratory tests with elevated levels of serum lipase, amylase in urine, blood, or ascitic fluid, and abnormal imaging findings. In the case reported, all criteria were met. Moreover, elevated serum triglyceride levels can aggravate the patient's severity score and prognosis. Therefore, aggressive treatment in this situation could decrease the morbidity and mortality of acute postpartum pancreatitis.

Therapeutic management usually consists of conservative treatment: fasting from food, intravenous fluid therapy, and management of symptoms. Cholecystectomy and sphincterotomy with endoscopic retrograde cholangiopancreatography are indicated for patients with choledocholithiasis associated with acute pancreatitis or cholangitis. Given the situation, the patient did not undergo surgery or any intervention; she was recovering well under conservative treatment and antibiotic therapy.

As genetic testing is unavailable in the emergency department, idiopathic hypertriglyceridemia can be considered the cause of disease in this situation.

Conclusion

This report aims to outline the importance of early correct diagnosis and management of abdominal pain in the emergency department. In addition, it outlines the possibility of acute pancreatitis in a postpartum woman even if she does not have the two most common risk factors encountered: gallstones or alcohol consumption.

Author's contributions

NA: Conceptualization, Data curation, Formal Analysis, Funding acquisition, Investigation, Methodology, Writing – original draft

PP: Methodology, Project administration, Supervision, Validation, Visualization, Writing – review & editing

Conflict of interest

None to declare

References

1. Arnold J, Martínez W, Oksenberg S, Oksenberg D. Pancreatitis aguda por hipercalcemia en el embarazo. Caso clínico [Acute pancreatitis due to hypercalcemia during pregnancy. Report of one case]. *Rev Med Chil.* 2019 Aug;147(8):1078-1081. Spanish. doi: 10.4067/S0034-98872019000801078. PMID: 31859975.
2. Yang TW, Peng CM, Tsai MC. An Unusual Cause of Acute Pancreatitis in a Young Woman. *Gastroenterology.* 2019 Sep;157(3):619-621. doi: 10.1053/j.gastro.2018.11.080. Epub 2019 Jan 4. PMID: 30615872.
3. Boukatta B, Sbai H, Laalim SA, Toughrai I, Houari N, El Bouazzaoui A, Kanjaa N. Pancréatite aigüe du post-partum: à propos d'un cas [Acute pancreatitis in postpartum: report of a case]. *Pan Afr Med J.* 2013 May 2;15:2. French. doi: 10.11604/pamj.2013.15.2.2359. PMID: 23847699; PMCID: PMC3708328.
4. Jallouli A, Baba H, Zeroual A, Ramraoui ME, Elguazzar A, Lahkim M, Khader AE, Barni RE. Pancréatite aigüe idiopathique du post-partum: difficultés diagnostiques (à propos d'un cas) [Postpartum idiopathic acute pancreatitis: diagnostic difficulties (case report)]. *Pan Afr Med J.* 2022 Jan 18;41:48. French. doi: 10.11604/pamj.2022.41.48.31342. PMID: 35317479; PMCID: PMC8917461.
5. Woods GN, Saitman A, Gao H, Clarke NJ, Fitzgerald RL, Chi NW. A Young Woman With Recurrent Gestational Hypercalcemia and Acute Pancreatitis Caused by CYP24A1 Deficiency. *J Bone Miner Res.* 2016 Oct;31(10):1841-1844. doi: 10.1002/jbmr.2859. Epub 2016 May 6. PMID: 27105398; PMCID: PMC5071127.
6. Cruciat G, Nemeti G, Goidescu I, Anitan S, Florian A. Hypertriglyceridemia triggered acute pancreatitis in pregnancy - diagnostic approach, management and follow-up care. *Lipids Health Dis.* 2020 Jan 4;19(1):2. doi: 10.1186/s12944-019-1180-7. PMID: 31901241; PMCID: PMC6942404.
7. Maringhini A, Dardanoni G, Fantaci G, Patti R, Maringhini M. Acute Pancreatitis During and After Pregnancy: Incidence, Risk Factors, and Prognosis. *Dig Dis Sci.* 2021 Sep;66(9):3164-3170. doi: 10.1007/s10620-020-06608-5. Epub 2020 Oct 21. PMID: 33085013.
8. Mauri M, Calmarza P, Ibarretxe D. Dyslipemias and pregnancy, an update. *Clin Investig Arterioscler.* 2021 Jan-Feb;33(1):41-52. English, Spanish. doi: 10.1016/j.arteri.2020.10.002. Epub 2020 Dec 9. PMID: 33309071.
9. Maringhini A, Lankisch MR, Zinsmeister AR, Melton LJ 3rd, DiMagno EP. Acute pancreatitis in the postpartum period: a population-based case-control study. *Mayo Clin Proc.* 2000 Apr;75(4):361-4. doi: 10.4065/75.4.361. PMID: 10761490.
10. Mechery J, Burch D. Postpartum pancreatitis. *J Obstet Gynaecol.* 2006 May;26(4):371. doi: 10.1080/01443610600618499. PMID: 16753696.
11. Mali P. Pancreatitis in pregnancy: etiology, diagnosis, treatment, and outcomes. *Hepatobiliary Pancreat Dis Int.* 2016 Aug;15(4):434-8. doi: 10.1016/s1499-3872(16)60075-9. PMID: 27498585.