

RESEARCH ARTICLE

Purple sweet potato (*Ipomoea batatas* L.) reduces the wound temperature and erythema in STZ-induced diabetic rats

Ratih Paramita Suprpto^{1*}, Heri Kristianto²

1. Department of Physiology, Faculty of Medicine, Universitas Brawijaya, Jl Veteran, East Java, Indonesia

2. School of Nursing, Faculty of Health Science, Universitas Brawijaya, Puncak Dieng Eksklusif, East Java, Indonesia.

Objective: Wound temperature is one of the wound biomarkers representing the wound healing progress. The diabetic wound is associated with a prolonged inflammation phase marked by an increasing wound temperature and erythematous wound. Purple sweet potato extract (PSP), an anthocyanin-rich plant, improved wound healing in both diabetic and non-diabetic wounds in animal studies. This study aims to know the effect of purple sweet potato ethanol extract on wound temperature and erythema in streptozotocin-induced diabetic rats.

Methods: Rats were divided into four groups: normal rats + gel placebo; diabetic rats + gel placebo; diabetic rats + PSP 10%; and diabetic rats + PSP 15%. Diabetes mellitus was induced by streptozotocin injection. After diabetic confirmation, the back of the rats was excised and the gel was administered daily for 14 days. The wound temperature was measured at the wound surface using infrared thermography on days 0, 3, 7, and 14. The wounds were photographed and erythema analysis was conducted using Corel Photo paint®.

Results: Diabetic wounds exhibited higher surface temperature compared with the normal wound ($37.08^{\circ}\text{C} \pm 0.29$ vs $35.13^{\circ}\text{C} \pm 0.46$) on day 14 of examination and topical application the purple sweet potato ethanol extract gel 10% and 15% markedly decreased the wound temperature at day 7 and 14 compared with the diabetes wound ($p < 0.0001$). Wound erythema was significantly reduced in the PSP 10% and 15% diabetic wound treatment groups on day 14 ($p < 0.05$).

Conclusion: Purple sweet potato extract gel treatment was found to have the potential to reduce inflammation in diabetic wounds.

Keywords: diabetes, wound temperature, erythema, wound healing, purple sweet potato ethanol extract

Received 21 June 2023 / Accepted 22 June 2024

Introduction

Wound healing is a normal biological mechanism in the body. It comprises several steps including inflammation, proliferation, and remodeling phases. The inflammatory phase consists of hemostasis, vasodilatation, infiltration, and recruitment of various immune cells that release proteases, and cytokines, and cause oxidative stress. The purpose of this phase is to prevent further damage, remove cellular debris, and prepare the wound bed for the proliferation phase which lasts 1-3 days [1]. However, the prolonged inflammatory phase, such as in diabetes mellitus, causes impaired wound healing and an increased risk of infection [2].

A measurable biomarker of inflammation is an increase in temperature. Various studies show that the practice of regular wound temperature monitoring is effective in detecting impending foot inflammation like diabetic foot ulcers, infection, and acute Charcot neuroarthropathy episodes [3–5]. In this regard, measurement using a handheld (non-contact) infrared thermometer is considered valuable equipment to assess diabetic foot ulcers in clinical practice [6]. Moreover, a recent human study shows that the baseline value of non-infected wound temperature is between $28\text{--}32^{\circ}\text{C}$. This range is suggested as the therapeutic range of wound healing [3]. In addition, skin or mucosal

inflammation manifests as erythema or redness in the skin or mucosa. In the clinical setting, observation of erythema of the skin or mucosa is useful to assess the inflammation grade. This color change is reflected in the skin or mucosa which could be measured objectively. One of the erythema measurements is using imaging methods, such as digital photography which is then analyzed using graphic software [7].

Numerous studies have shown that the administration of anti-inflammatory-rich agents could improve wound healings [8]. Anthocyanin, a natural pigment of purple in fruits and vegetables, possesses anti-inflammatory properties [9]. Purple sweet potato, among anthocyanin enrichment plants, has been reported for beneficial effects in wound healing in diabetic wounds in animal studies through its inflammatory properties [10,11]. This study aimed to examine the effect of purple sweet potato ethanol extract and the wound temperature and erythema of diabetic wounds in rats.

Methods

Experimental Animals

In this research, 20 healthy male *Rattus norvegicus* (± 200 gr) rats aged 8-10 weeks old were adapted in cages for seven days before the research started following the standard environmental condition, including light or dark conditions of 12:12 hours and room temperature at $25^{\circ} \pm 2^{\circ}\text{C}$.

* Correspondence to: Ratih Paramita Suprpto
E-mail: ratihparamita@ub.ac.id

They received a balanced diet and water administered ad libitum. The animal experiment was approved by the Ethics Committee of the Faculty of Medicine of Universitas Brawijaya No. 125/EC/KEPK/05/2018 date of ethics approval 31/May/2018. Animal research was performed at the Bioscience Institute of Universitas Brawijaya. Rats were divided into four groups (each group consisted of 5 rats), comprising a negative control group (normal rats), a positive control group (gel placebo-treated diabetic rats), a diabetic group treated with 10% purple sweet potato extract gel, and a diabetic group treated with 15% purple sweet potato extract gel. The dosage was chosen as a previous study using the peel of sweet potatoes showed effectiveness in wound healing with gel containing 10% concentration extract [12].

Diabetes and Wound Healing Models

To induce diabetes mellitus conditions, rats were injected intraperitoneally with streptozotocin (STZ). After seven days of adaptation, rats fasted for eight hours before STZ injection, but they were had free of water access to avoid dehydration. Streptozotocin (40 mg/kg body weight) was freshly prepared by dissolving in 0.1 mol/L citrate buffer (pH 4.5). A balanced diet and sucrose 20% were provided ad libitum to prevent hypoglycemia. Meanwhile, negative control rats were injected with citrate buffer (pH4.5) only. Fasting blood glucose was measured after eight hours of fasting without food. Afterward, blood glucose levels were measured using a commercial glucometer (Accucheck®), and the blood was taken from the incision of the rat tail using a lancet. Rats with fasting serum blood glucose of more than 250mg/dL on day seven after the STZ injection had been included in the research [13].

Excision Wound Models

All rats were anesthetized with an intraperitoneal injection of ketamine-xylazine of 50 mg/kg BW and 5 mg/kg BW, respectively [14]. Hairs on the back were shaved using an electric shaver, and the shaved area was disinfected with 70% alcohol. A 1.5 x 1.5 cm incision was performed on the shaved area using a sterilized surgical scissor. The wound excision was made on day seven after the diabetic condition was confirmed [15].

Vegetal Material and Preparation of Extracts

Roots of purple sweet potatoes (*Ipomoea batatas* L.) were acquired from farmers in Kawi Mountain in Malang, East Java. The extraction was performed in the Bioorganic Laboratory of Institut Teknologi Bandung. One kilogram of root peel of purple *Ipomoea batatas* L. was macerated in an ethanol-HCl 0.01% (14 hours). Then, the macerate was evaporated using a rotatory evaporator until a thick extract was obtained. Afterward, the anthocyanin content was measured using pH differential method by measuring the absorbance of the extract on pH 1 and 4 solution. The absorbance was measured in 521 nm and 700 nm wave-

lengths. The total anthocyanin content (TAC) was analyzed using this formula:

$$\text{TAC (\%)} = \frac{A \times \text{MW} \times \text{DF} \times 1000 \times V}{E \times W \times \text{Wt}}$$

A : The absorption (A 521 - A700) pH1 – (A521 - A700) pH4

MW: Molecular weight (449,2 g/mol)

DF: The Dilution factor

V: Final Volume (L)

E: Molar Extinction Coefficient (26.900 L/(mol. cm))

W: Cuvette Thickness (1 cm)

Wt: Extract Weight (g)

The concentration of anthocyanin was 0.132g/100g fresh product [16].

Preparation of Gels

The base gel formulation was prepared based on natrium carboxymethyl cellulose (Na-CMC), propylene glycol, and water. To obtain 10% and 15% gels, the extract was added to the base gel until the established concentration was obtained[17]. The gel concentration was based on a previous study using ipomoea batatas The extract gels were stored at room temperature. The gel was freshly prepared for every treatment at the Pharmacy Laboratory of Universitas Brawijaya.

Group of Treatment and Evaluation of Temperatures and Healing Activities

Placebo gel or purple sweet potato extract gel was daily applied to the dorsal wound of each group once for 14 days after the excision. The treatment apparatus was sterilized before usage. The wound temperature was measured daily before gel application using an infrared thermometer (Krisbow®) at a constant 15 cm distance level. The temperatures were recorded in degrees Celsius (°C)[3]. For the treatment, the wound was cleaned with normal saline and dried using a sterile Kassa. Then, the gel was administered to the wound area. The wound size was measured and photographed using a digital camera on days 0, 3, 7, and 14 of wound excision [7].

Wound Erythema Analysis

The wounds were consistently photographed at 15 cm from the wound in the same position for all rats. Digital analysis was performed based on color segmentation using graphic software, Corel Paint PhotoshopX7 [7]. The point analysis was taken from all four corners of each picture. Then, the erythema value changes (EVC) (%) were obtained using this formula.

$$\text{EVC (\%)} = \frac{\text{Specific day EV} - \text{Initial day EV}}{\text{Initial day EV}} \times 100$$

EV: Erythema Value

Statistical Analyses

All data are presented as mean \pm standard deviation. Statistical analyses were performed using the GraphPad Prism 8. Differences between groups were calculated using a two-way ANOVA. Statistical significance was set at $p < 0.05$.

Results

Wound Temperature

Twenty rats were divided into 4 groups including five for each group: normal rats, diabetic rats, diabetic + PSP 10%, and diabetic rats + PSP 15%. Two rats died during the experiment, each in the positive control and diabetic rats + PSP 10% group due to excessive hyperglycemia, despite the similar dosage of STZ, weight, and acclimatization. However, the rats included were 5 in each group as we had the spare rats for STZ-treated rats. The wound is presented in Figure 1A-D. Wound temperature was measured on days 0, 3, 7, and 14. The results were shown in Table 1 and Table 2. Basal temperatures at days 0 and 3 were similar in all groups around $35.39^{\circ}\text{C} - 36.35^{\circ}\text{C}$. The temperature of normal rats was slightly increased at day 3 indicating the inflam-

mation phase of wound healing then consistently reduced until the end observation at day 14. In contrast, the basal temperature of diabetic wound rats steadily increased during the observation until day 14. Interestingly, treatment with purple sweet potato gel 10% and 15% remarkably inhibited the raised temperature in the wound of diabetic rats at day 7, significantly different compared with the dorsal wound temperature of placebo gel-treated diabetic rats ($p < 0.0001$). Moreover, on the last day of observation, the wound temperatures of PSP10% and PSP15% treatment groups were significantly reduced ($p < 0.0001$) compared with the placebo gel-treated diabetic rats.

Erythema Changes

The erythema values were evaluated from wound photographs and red color segmentation was measured using Corel photo paint. The erythema changes in the wound healing were expressed as a percentage of the wound erythema at the time of observation compared with the wound erythema on day 0 (Figure 2). The erythema values were sharply increased during days 0-3 in all groups compared to day 0 (baseline). Interestingly, in PSP extract

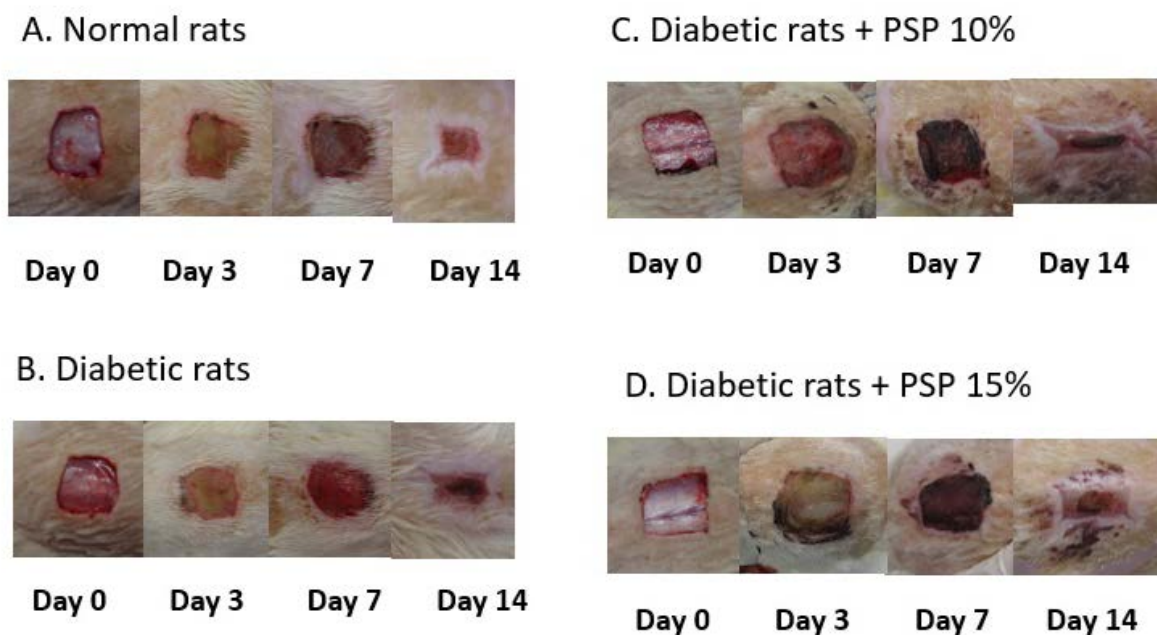


Fig 1A-D. Representative pictures on the dorsal wound of rats on days 0, 3, 7, and 14 of treatments A. normal rats treated with gel placebo B. diabetic rats treated with gel placebo C. diabetic rats treated with Purples sweet potato extract gel (PSP) 10% D. diabetic rats treated with Purples sweet potato extract gel (PSP) 15%. (n=5)

Table 1. The temperature of the wound bed

C	Temperature ($^{\circ}\text{C}$)			
	Normal rats	Diabetic rats	Diabetic rats + PSP 10%	Diabetic rats + PSP 15%
0	36.15 ± 0.14	36.35 ± 0.21	36 ± 0.27	35.9 ± 0.61
3	36.53 ± 0.16	36.6 ± 0.07	35.75 ± 0.3	35.93 ± 0.62
7	36 ± 0.51^a	36.52 ± 0.72^a	33.52 ± 0.6^b	33.74 ± 0.85^b
14	35.13 ± 0.46^a	37.075 ± 0.29^b	34.53 ± 1.06^a	34.94 ± 0.19^a

Superscripts (^{a,b}) with similar alphabets are not significant whereas those with different alphabets are significant, $p < 0.0001$ (n=5). For example, wound temperatures in diabetic rats + PSP 10% and diabetic rats + PSP 15% are differed significantly compared with wound temperatures of normal and diabetic rats.

Table 2. Two-way ANOVA and Tukey’s Multiple Comparisons Test Comparing Each Group’s Temperatures value at day 0, 3, 7, and 14

Tukey’s multiple comparisons test	Mean diff.	95,00% CI of diff.	Significant?	Summary	Adjusted P Value
Day 0					
Normal Rats vs. Diabetic Rats	-0.2000	-1.181 to 0.7811	No	ns	0.9494
Normal Rats vs. Diabetic Rats + PSP 10%	0.1500	-0.8311 to 1.131	No	ns	0.9776
Normal Rats vs. Diabetic Rats + PSP 15%	0.2500	-0.6275 to 1.128	No	ns	0.8754
Diabetic Rats vs. Diabetic Rats + PSP 10%	0.3500	-0.7247 to 1.425	No	ns	0.8254
Diabetic Rats vs. Diabetic Rats + PSP 15%	0.4500	-0.5311 to 1.431	No	ns	0.6223
Diabetic Rats + PSP 10% vs. Diabetic Rats + PSP 15%	0.1000	-0.8811 to 1.081	No	ns	0.9931
Day 3					
Normal Rats vs. Diabetic Rats	-0.06667	-1.048 to 0.9144	No	ns	0.9979
Normal Rats vs. Diabetic Rats + PSP 10%	0.7833	-0.1978 to 1.764	No	ns	0.1619
Normal Rats vs. Diabetic Rats + PSP 15%	0.6000	-0.2775 to 1.478	No	ns	0.2807
Diabetic Rats vs. Diabetic Rats + PSP 10%	0.8500	-0.2247 to 1.925	No	ns	0.1684
Diabetic Rats vs. Diabetic Rats + PSP 15%	0.6667	-0.3144 to 1.648	No	ns	0.2860
Diabetic Rats + PSP 10% vs. Diabetic Rats + PSP 15%	-0.1833	-1.164 to 0.7978	No	ns	0.9603
Day 7					
Normal Rats vs. Diabetic Rats	-0.5250	-1.506 to 0.4561	No	ns	0.4963
Normal Rats vs. Diabetic Rats + PSP 10%	2.475	1.494 to 3.456	Yes	****	<0.0001
Normal Rats vs. Diabetic Rats + PSP 15%	2.260	1.340 to 3.180	Yes	****	<0.0001
Diabetic Rats vs. Diabetic Rats + PSP 10%	3.000	1.925 to 4.075	Yes	****	<0.0001
Diabetic Rats vs. Diabetic Rats + PSP 15%	2.785	1.765 to 3.805	Yes	****	<0.0001
Diabetic Rats + PSP 10% vs. Diabetic Rats + PSP 15%	-0.2150	-1.235 to 0.8046	No	ns	0.9444
Day 14					
Normal Rats vs. Diabetic Rats	-1.942	-2.923 to -0.9606	Yes	****	<0.0001
Normal Rats vs. Diabetic Rats + PSP 10%	0.6083	-0.3728 to 1.589	No	ns	0.3658
Normal Rats vs. Diabetic Rats + PSP 15%	0.1933	-0.7270 to 1.114	No	ns	0.9450
Diabetic Rats vs. Diabetic Rats + PSP 10%	2.550	1.475 to 3.625	Yes	****	<0.0001
Diabetic Rats vs. Diabetic Rats + PSP 15%	2.135	1.115 to 3.155	Yes	****	<0.0001
Diabetic Rats + PSP 10% vs. Diabetic Rats + PSP 15%	-0.4150	-1.435 to 0.6046	No	ns	0.7062

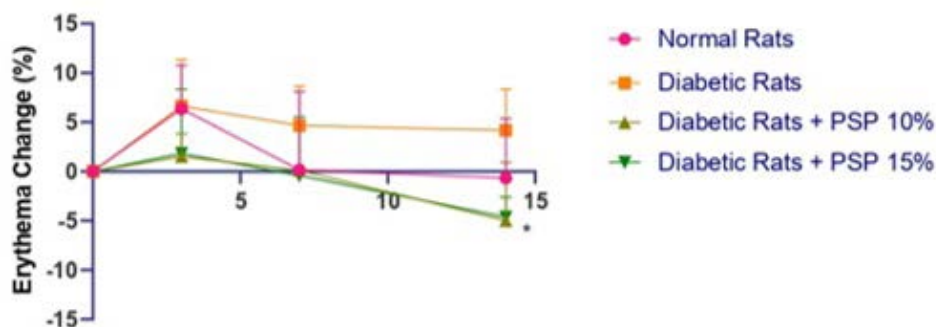


Fig 2. The evolution of erythema value (%) of dorsal wounds of normal and diabetic rats on days 0, 3, 7, 14 and daily topical application of gel-based in purple sweet potato extracts and controls. The results are shown as mean and standard error, statistically analyzed with Two-way ANOVA and post hoc test. (*) indicates statistically different compared to the diabetic rats $p < 0.05$. (n=5).

gel-treated diabetic rats, the erythema changes were lower compared with diabetic and normal rats. On day 3 until 7, the erythema value was still raised indicating the prolonged inflammation in diabetic wounds. PSP treatment resulted in reduced erythema changes compared with diabetic and normal rats. Until day 14, the wound bed of diabetic rats remained elevated compared with all groups. Interestingly, a wound of diabetic rats treated with PSP extract gel 10% and 15% experienced markedly reduced erythema on day 14 of wound excision as compared to the diabetic rats treated with gel-based only ($p < 0.05$).

Discussion

This present study showed that purple sweet potato gel extract significantly inhibited the increased wound tem-

perature and erythema in diabetic rats. In normal rats, the wound temperature slightly increased on day 3 indicating an inflammation state then reduced afterward. However, in diabetic rats, the wound temperature remained increasing until the end of the experiment on day 14. The wound erythema values did a similar pattern as the temperature change, which was constantly increased in the diabetic rats from the day of wound excision until day 14 while reduced in normal rats after day 3 of injury. The topical application of the purple sweet potato gel extract markedly reduced the wound temperature and erythema of diabetic rats at the same level of wound temperature as normal rats.

Poor hyperglycemic control in diabetes mellitus generates various devastating products such as inflammatory mediators, oxidative stress, and advanced glycation end

products (AGEs) leading to endothelial dysfunction, neuropathy, and immunopathy [8, 13]. Therefore, diabetes is associated with a prolonged inflammation state. During the inflammation, the release of inflammatory mediators causes vasodilatation allowing more blood to reach the inflamed areas resulting in an increased temperature in the inflamed areas. In addition, enhanced enzymatic tissue autolysis in diabetics contribute to the warmer temperature [19]. For this reason, in this study, the wound temperature and erythema of diabetic rats remained higher until day 14 compared to normal rats.

Ethanol extract from purple sweet potato 10% and 15% improved wound healing in diabetic rats. Previous studies also proved the effect of purple sweet potato extract in accelerating wound healing in normal rats. In this regard, purple sweet potato has been known as rich in anthocyanin of its purple color. The major anthocyanin aglycones found in sweet potatoes are peonidin and cyanidin. The purple sweet potato extract treatment reduces the protein level of Nf- κ B, TNF- α , and IL-6 and the production of NO in LPS-induced inflammation in macrophage cells [9]. In addition, purple sweet potato extract contains the highest flavonoid content and performs lipoxygenase inhibition at the lowest concentration compared with white and orange sweet potato extracts [20]. Further supports that purple sweet potato is a potent anti-inflammatory.

Investigation of thermography in wound monitoring has begun in the early 1960s. Increased temperature is a sign of inflammation or infection. Several tools could be used in clinical and laboratory settings, however, measurement using an infrared thermometer has proven as a useful instrument for detecting inflammation and staging of the disease severity. Moreover, it is also non-invasive, fast acquisition time, and is inexpensive. Various studies show that the clinical practice of regular wound temperature monitoring is effective in detecting impending foot inflammation like diabetic foot ulcers, infection, and acute Charcot neuroarthropathy episodes [3–5]. Erythema or skin redness observation is also useful for inflammation monitoring as skin or mucosal inflammation is reflected on the skin or mucosal surface. For clinical or research evaluation, skin redness could be measured quantitatively, such as using graphic software. In this present study, it is proved that a direct-temperature measurement using an infrared thermometer and image digital analysis could detect the enhanced inflammation of the dorsal wound of an STZ-induced diabetic rat model. In addition, other studies that purple sweet potato extract gel reduced the increased temperature and skin erythema of dorsal wounds of diabetic rats. The limitations of this study include the small sample size and lack of the inflammatory markers measured.

Conclusion

The present study showed that purple sweet potato ethanol extract prepared as gel formulations with a concentration 10% and 15% had anti-inflammatory properties in diabet-

ic wound as compared to the gel placebo-treated diabetic rats. The composition of bioactive metabolites of purple sweet potato induced this anti-inflammation activity and hence, purple sweet potato might be a potent herbal medicine in diabetic wound healing.

Acknowledgements and funding resources

The Authors would like to express gratitude to Universitas Brawijaya for the research facility and financial support.

Authors` Contribution

RTH: Conceptualization, Data curation, Formal Analysis, Funding acquisition, Investigation, Methodology, Project administration, Resources, Supervision, Validation, Visualization, Writing – original draft.

HK: Conceptualization, Data curation, Formal Analysis, Investigation, Methodology, Software, Supervision, Validation, Visualization, Writing – review & editing.

Conflict of Interests

The authors declare that there is no conflict of interest regarding the publication of this paper.

References

- Landén NX, Li D, Ståhle M. Transition from inflammation to proliferation: a critical step during wound healing. *Cell Mol Life Sci.* 2016;73(20):3861–85.
- Dasari N, Jiang A, Skochdopole A, Chung J, Reece EM, Vorstenbosch J, et al. Updates in Diabetic Wound Healing, Inflammation, and Scarring. *Semin Plast Surg.* 2021;35(3):153–8.
- Gethin G, O'Connor GM, Abedin J, Newell J, Flynn L, Watterson D, et al. Monitoring of pH and temperature of neuropathic diabetic and nondiabetic foot ulcers for 12 weeks: An observational study. *Wound Repair Regen.* 2018;26(2):251–6.
- Lavery LA, Petersen BJ, Linders DR, Bloom JD, Rothenberg GM, Armstrong DG. Unilateral remote temperature monitoring to predict future ulceration for the diabetic foot in remission. *BMJ Open Diabetes Res Care.* 2019;7(1).
- de Araujo AL, Negreiros FD da S, Florêncio RS, de Oliveira SKP, da Silva ARV, Moreira TMM. Effect of thermometry on the prevention of diabetic foot ulcers: a systematic review with meta-analysis*. *Rev Lat Am Enfermagem.* 2022;30.
- Percianu ER, Buse AM. The Handheld Infrared Thermometry in the Diabetic Foot-Useful but Debatable Technique. *Rom J Diabetes, Nutr Metab Dis.* 2020;27(3):298–302.
- Andreas Neubauer and Harald Schnidar. Methods for assessing erythema [Internet]. Vol. 1. 2014. p. 1–49. Available from: <https://patents.google.com/patent/EP2976013A1/en>
- Albahri G, Badran A, Hijazi A, Daou A, Baydoun E, Nasser M, et al. The Therapeutic Wound Healing Bioactivities of Various Medicinal Plants. *Life.* 2023;13(2).
- Sugata M, Lin CY, Shih YC. Anti-Inflammatory and Anticancer Activities of Taiwanese Purple-Fleshed Sweet Potatoes (*Ipomoea batatas* L. Lam) Extracts. *Biomed Res Int.* 2015;2015.
- Ningrum DD, Padaga MC, Fauzi A. The effect of purple sweet potato (*Ipomoea batatas* L.) extract gel toward TNF- α expression and skin collagen density on rats (*Rattus norvegicus*) with open wound models. *J Phys Conf Ser.* 2020;1430(1).
- Kristianto H, Nurachmah E, Gayatri D, Geraghty T, LaPorta G, Singh R, et al. The effect of purple sweet potato (*Ipomoea batatas* L.) extract gel toward TNF- α expression and skin collagen density on rats (*Rattus norvegicus*) with open wound models. *Antioxidants* [Internet]. 2021;13(1):1–14. Available from: <http://dx.doi.org/10.1038/nm.3887%5Cnhttp://www.ncbi.nlm.nih.gov/pubmed/26076037%5Cnhttp://www.pubmedcentral.nih.gov/articlerender.fcgi?artid=PMC4631120>
- Panda V, Sonkamble M PS. Functional Foods in Health and Diseases. *Funct Foods Heal Dis.* 2011;1(10):403–15.
- Dewi KN, Kristianto H, Indra MR. The Effect of Squid Extract (Loligo

- Sp) on TNF- α and TGF- β 1 Serum Levels during Wound Healing in Streptozotocin-induced Diabetic Rats. *Makara J Heal Res.* 2016;20(3).
14. Sutejo IR, Hasanah AN, Sudarko FR. Ethanol extract of Edamame (*Glycine max L. merril*) enhance second degree burn wound healing through modulating of hydroxyproline levels and increasing epithelial thickness. *Acta Marisiensis - Ser Medica.* 2022;68(2):55–60.
 15. Atiba A, Nishimura M, Kakinuma S, Hiraoka T, Goryo M, Shimada Y, et al. Aloe vera oral administration accelerates acute radiation-delayed wound healing by stimulating transforming growth factor- β and fibroblast growth factor production. *Am J Surg [Internet].* 2011;201(6):809–18. Available from: <http://dx.doi.org/10.1016/j.amjsurg.2010.06.017>
 16. Alam FM, Kurnianingsih N, Fatchiyah F. Phytochemical Analysis of Purple Sweet Potatoes (*Ipomoea batatas*) Roots Extract From Lawang and Kawi Mountain Cultivar, East Java, Indonesia. *J Exp Life Sci.* 2022;12(1):17–22.
 17. Komorowska P, Róžańska S, Róžański J. Effect of the degree of substitution on the rheology of sodium carboxymethylcellulose solutions in propylene glycol/water mixtures. *Cellulose.* 2017;24(10):4151–62.
 18. Kristianto H, Nurachmah E, Gayatri D. Peningkatan Ekspresi Transforming Growth Factor Beta 1 (TGF β 1) Pada Luka Diabetes Melitus Melalui Balutan Modern. *J Keperawatan Indones.* 2010;13(1):20–5.
 19. Bus SA. Innovation in plantar pressure and foot temperature measurements in diabetes. *Diabetes Metab Res Rev.* 2016;32(Suppl. 1):221–6.
 20. Sendangratri, Handayani R, Elya B. Inhibitory effects of different varieties of sweet potato (*Ipomoea batatas L.*) tubers extracts on lipoxxygenase activity. *Pharmacogn J.* 2019;11(6):1195–8.