

CASE REPORT

Primary intraosseous mucoepidermoid carcinoma - A case report of 2 rare occurrences in the maxilla

Sivan Sathish^{1*}, Ankita Jain², Pradeep Tangade², Haritma Nigam¹, Vaishali Malik¹, Priya Singh¹

1. Department of Oral Medicine and Radiology, Teerthanker Mahaveer Dental College and Research Centre, Moradabad, Uttar Pradesh, India

2. Department of Public Health Dentistry, Teerthanker Mahaveer Dental College and Research Centre, Moradabad, Uttar Pradesh, India

Introduction: Primary intraosseous mucoepidermoid carcinoma is a rare malignancy originating from minor or ectopic salivary gland tissue within the jawbones, presenting diagnostic challenges, especially in young patients. This article is aimed at oral and maxillofacial radiologists, surgeons, oncologists, and dental practitioners who encounter such cases, highlighting the importance of early recognition for effective treatment planning.

Case Presentation: Two cases of primary intraosseous mucoepidermoid carcinoma in the maxilla are presented. The first involves a 27-year-old female with pain and swelling in the left upper jaw. Cone-beam computed tomography showed a multicystic hypodense lesion with bicortical expansion and palatal perforation. The second case features a 15-year-old with similar radiographic findings but with additional lymph node involvement, indicating a more aggressive disease. The first case was localized and painful, while the second was painless, with the lesion extending into the maxillary sinus. Diagnoses were confirmed via fine needle aspiration cytology and histopathology, followed by surgical resection.

Conclusion: These cases highlight the need for clinicians to consider primary intraosseous mucoepidermoid carcinoma as a differential diagnosis for jaw swellings across all ages. Advanced imaging, particularly cone-beam computed tomography, is crucial for precise diagnosis and early intervention, leading to improved patient outcomes.

Keywords: primary intraosseous mucoepidermoid carcinoma, maxilla, jaw lesions

Received 9 October 2024 / Accepted 30 October 2024

Introduction

Salivary gland neoplasms are rare, accounting for only about three to five percent of all head and neck tumors [1]. Among these, those that originate within the bone are even more uncommon. Intraosseous mucoepidermoid carcinoma represents just about two percent of all reported cases of mucoepidermoid carcinoma [2]. This condition arises from minor salivary glands or ectopic salivary gland tissue remnants in the maxillary or mandibular regions, which undergo neoplastic transformation [3]. This report presents two rare cases of primary intraosseous mucoepidermoid carcinoma of the maxilla, including one involving a teenage patient—an exceptionally rare occurrence. Both cases shared common features like occurrence in a younger age group (under 30 years), where this condition is scarce and clinically, both cases were presented with dome-shaped swellings in the palatal mucosa, with cone-beam computed tomography revealing bicortical expansion, palatal bone perforation, and multicystic hypodense lesions, demonstrating a consistent pattern for this condition. However, there were distinct differences among these two cases, underscoring the need for careful diagnosis and treatment planning. The first patient had a painful palatal swelling with mucous discharge, and the disease was localized in the maxilla without any metastatic cervical lymph node involvement. In contrast, the second case presented

as a painless palatal swelling that extended into the maxillary sinus and with metastatic cervical lymph nodes. These cases highlight the importance of using advanced radiographic imaging like CBCT for early diagnosis to prevent metastasis.

Case Presentation

Case Report 1

A 27-year old female patient came to the Department of Oral Medicine and Radiology with a chief complaint of a painful swelling in her left upper jaw region for the past 3 years. The history of presenting illness reveals that the swelling was gradual in onset and associated with pain and mucous discharge. The pain was intermittent in nature, dull in intensity, and non-radiating in character. There was no history of dental infection or trauma. There was no significant past medical history.

On extraoral examination, facial asymmetry was noted with a diffuse swelling on the left side of the face due to the intraoral swelling (Figure 1A).

On intraoral examination, on inspection, a dome shaped swelling was noted in the posterior region of the left maxilla. It extended anteriorly from 24 and posteriorly up to 28. On palpation, the swelling was tender, firm in consistency, and the surface texture was undulating. The overlying mucosa appears edematous. Exudation of mucus material was noted. Grade I mobility was noted in 27 (Figure 1B).

* Correspondence to: Sivan Sathish
E-mail: sivansathishmfs@yahoo.co.in

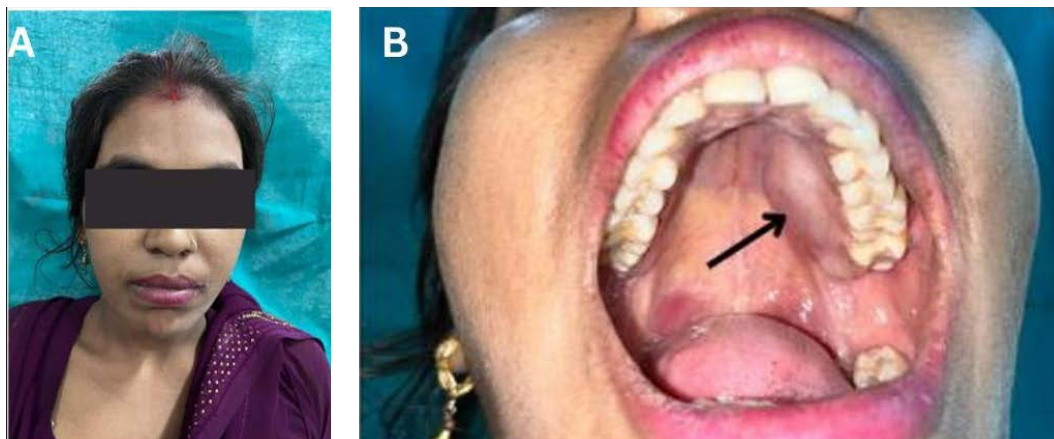


Fig. 1 (A). Extraoral swelling on left side of the face (B). Intraoral dome-shaped swelling

Cone-beam computed tomography (CBCT) revealed multicystic hypodense lesion extending from 24, 25, 26, and 27. Bicortical expansion of the buccal and palatal plate was noted along with perforation of the palatal bone (Figure 2). A provisional diagnosis of primary intraosseous mucoepidermoid carcinoma was given and was later confirmed with fine needle aspiration cytology (FNAC) and incisional biopsy. The cytological category was defined as malignant. Microscopic examination revealed clusters of atypical mucous cells with cystic spaces in a fibrous stroma. The final diagnosis was primary intraosseous mucoepidermoid carcinoma of left posterior maxilla from 24 to 27 region. Surgical resection was recommended for the localized disease, focusing on complete removal with clear margins. The treatment was confined to the affected area, ensuring thorough excision. Given the absence of lymph node involvement

and the localized nature of the condition, the expected prognosis is favorable.

Case Report 2

A 15-year old patient came to the Department of Oral Medicine and Radiology with a chief complaint of a painless swelling in her left upper jaw region for the past 5 years. The history of presenting illness revealed that the swelling was gradual in onset and it grew slowly to attain the present state. The swelling not associated with any pain. Patient had a history of bronchial asthma for the past 7 years with no significant dental history.

Extraoral examination did not reveal any facial asymmetry. On palpating lymph nodes, a solitary, firm, non-tender, and immobile (fixed) lymph node, measuring about 1 centimeter in diameter was noted in the submandibular

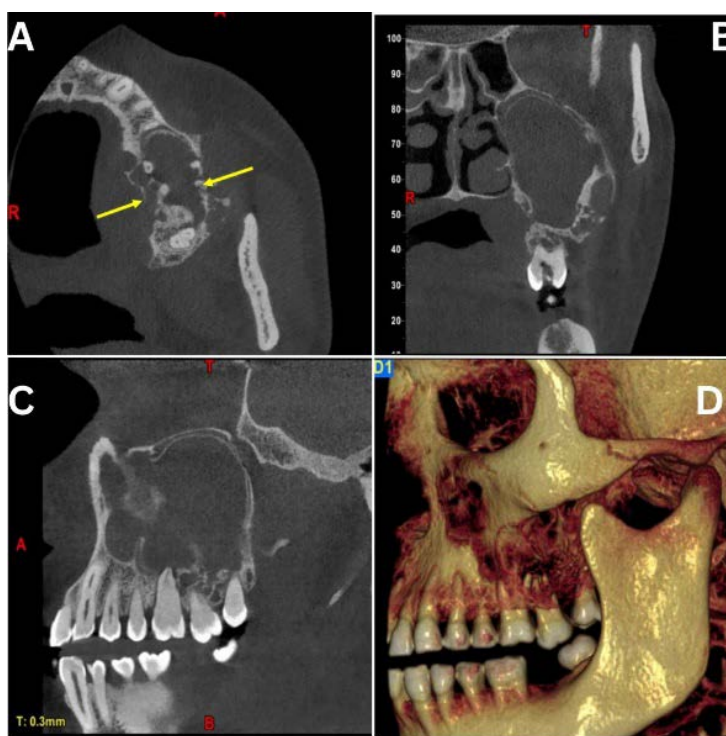


Fig. 2 (A, B) CBCT image showing bicortical expansion of buccal and lingual cortical plates of maxilla; (C,D) CBCT image showing multicystic hypodense lesion extending from 24 to 27

region. The skin overlying the lymph node appeared normal without any signs of warmth or redness. On intra oral examination, on inspection, a dome shaped swelling in the left maxillary jaw region extending anteriorly from 23 region posteriorly up to 27. On palpation, all the inspector findings were confirmed. The swelling was firm in consistency and the surface texture was undulating (Figure 3A).

Cone-beam computed tomography images revealed multicystic hypodense lesion extending from 23, 24, 25, 26, and 27 and invading the maxillary sinus. Buccal and lingual cortical expansion with palatal perforation was noted (Figure 3B). Magnetic resonance imaging (MRI) of the face and neck showed heterogeneously enhancing solid cystic lesion involving hard palate on the left side with extension into the left maxillary sinus. FNAC revealed clusters and fragments of atypical cells with high nuclear cytoplasmic ratio and irregular nuclear membrane in a necroinflammatory hemorrhagic mucinous background. The final diagnosis was primary intraosseous mucoepidermoid carcinoma of left maxilla from 23 to 27 region. Surgical resection was advised, but due to the extent of the disease, a more comprehensive approach was required. The lesion's spread into the maxillary sinus and lymph node involvement necessitated a more aggressive surgical strategy to ensure clear margins. The presence of lymphatic involvement and the extent of the tumor suggests a more guarded prognosis, requiring close post-treatment monitoring for any signs of recurrence.

Discussion

Primary intraosseous mucoepidermoid carcinoma is a rare condition, typically occurring in the fourth or fifth decade of life. The cases presented here highlight the unusual occurrence in younger patients, underscoring the diagnostic challenge of early-onset cases. Such occurrences are often overlooked, as clinicians may not expect this carcinoma in adolescents or young adults.

The diagnostic process for intraosseous mucoepidermoid carcinoma can be challenging due to its similarities with other odontogenic cysts and tumors. According to established criteria, diagnosing mucoepidermoid carcinoma of primary intraosseous origin requires: (i) radiological evidence of intraosseous destruction, (ii) exclusion of other primary odontogenic lesions or metastatic tumors, and (iii) confirmation through histopathological examination [8-9]. In both of our cases, these diagnostic criteria were meticulously followed, ensuring accurate identification of the disease.

Clinically, primary intraosseous mucoepidermoid carcinoma presents as a firm swelling, which can be painful or painless [4]. Radiologically, it appears as multilocular, mixed radiopaque-radiolucent lesions, consistent with findings from Chan et al., who reported cortical expansion, perforation, and extension into soft tissues [5]. In both cases, cone-beam computed tomography (CBCT) revealed multicystic hypodense lesions with bicortical expansion and perforation, aiding in detailed anatomical assessment.

Differential diagnosis is essential as the carcinoma resembles other odontogenic cysts and tumors, such as keratocystic odontogenic tumors, glandular odontogenic cysts, and ameloblastomas, all of which can present with a multicystic appearance [6]. Histopathological examination showing mucous, epidermoid, and intermediate cells confirmed the diagnosis in both cases [7].

Treatment involved surgical resection, tailored to disease extent. Radiotherapy was added in the second case due to lymph node involvement and maxillary sinus invasion. Literature indicates that treatment should account for tumor stage, extension, and metastasis, with mandatory long-term follow-up to monitor recurrence. Prognostic factors, such as tumor grade, cortical expansion, and lymph node involvement, are crucial [8]. Studies by de Souza et al. show that high-grade tumors are more aggressive, with a

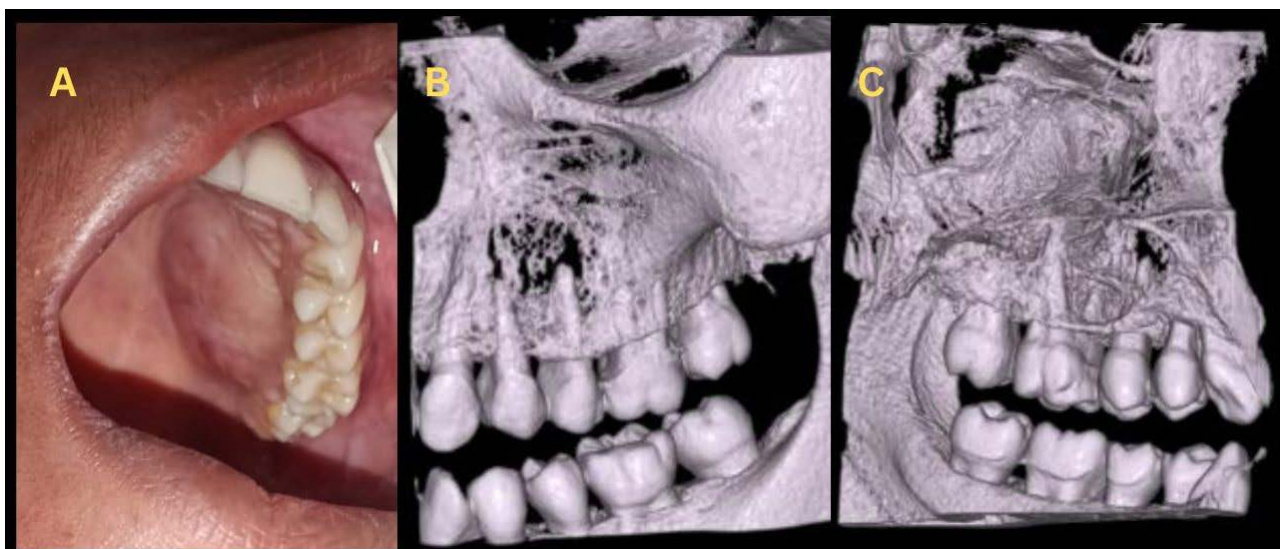


Fig. 3 (A) Intraoral dome shaped swelling (B, C) CBCT images showing multicystic hypodense lesions extending from 24 to 27 and involvement of maxillary sinus

higher metastasis risk, leading to poorer outcomes. Cortical destruction or perforation, seen in our cases, is also linked to a higher likelihood of local recurrence and surgical challenges [9].

Both cases reflect the typical diagnostic and radiological features described in the literature, underscoring the value of CBCT and histopathological examination. The occurrence of primary intraosseous mucoepidermoid carcinoma in a 15-year-old, however, remains exceptionally rare, stressing the need for clinician awareness to avoid diagnostic delays. Early surgical intervention, as applied here, is crucial for managing disease progression.

The strengths of our approach included advanced imaging techniques like three-dimensional CBCT for precise lesion evaluation and histopathology for accurate diagnosis. Prompt surgical management based on these findings led to favorable outcomes. A limitation was the delayed recognition of the disease's extent in the second case, necessitating more extensive treatment, underscoring the need for vigilance, especially in younger patients who may not present typical malignancy signs.

Recognizing prognostic factors, such as tumor grade, cortical expansion, and lymphatic involvement, is essential for optimizing patient management. Early, accurate diagnosis and a multidisciplinary approach are vital to improving outcomes in cases of primary intraosseous mucoepidermoid carcinoma.

Conclusion

Primary intraosseous mucoepidermoid carcinoma is a tumor that requires careful consideration when it comes to the diagnosis and treatment planning. It should be recognized as a potential diagnosis in patients with jaw swellings, regardless of their age and location. The radiographic images provided by CBCT can be pivotal as it reveals the multicystic appearance and volumetric changes associated with the lesion. Early identification through such advanced imaging modalities helps improve the prognosis.

Authors' Contribution

SS (Formal analysis; Investigation; Methodology; Patient Care; Validation; Visualization; Writing – original draft; Writing – review & editing)

AJ (Conceptualization; Data curation; Validation; Visualization; Writing – original draft; Writing – review & editing)

ing)

PT (Conceptualization; Data curation; Validation; Visualization; Writing – original draft; Writing – review & editing)

HN (Conceptualization; Data curation; Validation; Visualization; Writing – original draft; Writing – review & editing)

VM (Data curation; Formal analysis; Investigation; Methodology; Patient Care; Validation; Visualization; Writing – review & editing)

PS (Conceptualization; Data curation; Formal analysis; Visualization; Writing – original draft; Writing – review & editing)

Conflict of Interest

None to declare.

Ethical Statement

The patients have given permission to publish this case report.

References

- Galdirs TM, Kappler M, Reich W, Eckert AW. Current aspects of salivary gland tumors - a systematic review of the literature. *GMS Interdiscip Plast Reconstr Surg DGPW*. 2019 Aug 2;8:Doc12.
- Merna C, Kita A, Wester J, Diaz-Aguilar D, Goldstein JD, Palma Diaz F, Blackwell K, St John MA. Intraosseous mucoepidermoid carcinoma: Outcome review. *Laryngoscope*. 2018 May;128(5):1083-1092.
- Atarbashi Moghadam S, Atarbashi Moghadam F. Intraosseous mucoepidermoid carcinoma: report of two cases. *J Dent (Shiraz)*. 2014 Jun;15(2):86-90.
- Namin AK, Moshref M, Shahoon H, Mashhadi A, Khojasteh A. Intraosseous mucoepidermoid carcinoma of the maxilla in a teenager: a case report and review of literature. *Oral Surg Oral Med Oral Pathol Oral Radiol Endod*. 2005 Dec;100(6):e93-6. Erratum in: *Oral Surg Oral Med Oral Pathol Oral Radiol Endod*. 2009 Oct;108(4):641.
- Chan KC, Pharoah M, Lee L, Weinreb I, Perez-Ordóñez B. Intraosseous mucoepidermoid carcinoma: a review of the diagnostic imaging features of four jaw cases. *Dentomaxillofac Radiol*. 2013;42(4):20110162.
- Nallamilli SM, Tatapudi R, Reddy RS, Ravikanth M, Rajesh N. Primary Intraosseous Mucoepidermoid Carcinoma of the Maxilla. *Ghana Med J*. 2015 Jun;49(2):120-3.
- Kumar SM, Chandramouli P, Kailasam S, Raghuram PH, Sateesh S, Karpagavalli. Applications of cone-beam computed tomography in dentistry. *Journal of Indian Academy of Oral Medicine and Radiology* 23(4):p 593-597, Oct–Dec 2011.
- Maremonti P, Califano L, Mangone GM, Zupi A, Guida C. Intraosseous mucoepidermoid carcinoma. Report of a long-term evolution case. *Oral Oncol*. 2001 Jan;37(1):110-3.
- de Souza LL, Pontes FSC, Pontes HAR, Neto NC, de Carvalho WRS, Guimarães DM. Central mucoepidermoid carcinoma: An up-to-date analysis of 147 cases and review of prognostic factors. *J Craniomaxillofac Surg*. 2018 Jan;46(1):162-167.