

RESEARCH ARTICLE

Comparative non-invasive strategies for managing dental white spot lesions: Contribution to the study of enamel remineralization

Alessandro Golia¹, Alessandro Stellino¹, Nicola D'Andrea¹, Oana Elena Stoica², Kovács-Ivacson Andrea Csinszka³, Monica Dana Monea³, Alexandra Mihaela Stoica^{3*}

1. Faculty of Dental Medicine, George Emil Palade University of Medicine, Pharmacy, Science, and Technology of Targu Mures, Romania

2. Department of Pedodontics, Faculty of Dental Medicine, George Emil Palade University of Medicine, Pharmacy, Science, and Technology of Targu Mures, Romania

3. Department of Odontology and Oral Pathology, Faculty of Dental Medicine, George Emil Palade University of Medicine, Pharmacy, Science, and Technology of Targu Mures, Romania

White spot lesions (WSLs) are an early sign of enamel demineralization, requiring effective non-invasive treatments to restore esthetics and prevent progression. This study aimed to evaluate the effectiveness of fluoride varnish (GC MI Varnish) and resin infiltration (Icon Vestibular) in terms of esthetic improvement, remineralization, and sensitivity reduction. The study is primarily addressed to general dental practitioners, pediatric dentists, orthodontists, and restorative specialists who routinely encounter white spot lesions (WSLs) in both adolescent and adult patients. It is also relevant to dental researchers and students interested in minimally invasive treatment strategies and advancements in enamel remineralization. A total of 47 patients with non-cavitated WSLs were randomly assigned to two treatment groups: Fluoride Group ($n = 24$) received topical fluoride varnish applications and Icon Group ($n = 23$) underwent resin infiltration treatment. Statistical analysis was performed using an independent t-test ($p < 0.05$). The Icon Group showed an immediate reduction in white spot visibility ($p < 0.01$), while the Fluoride Group demonstrated gradual esthetic improvement over three months ($p < 0.05$). Fluoride varnish significantly enhanced enamel remineralization and reduced dentinal hypersensitivity ($p < 0.05$), whereas resin infiltration primarily stabilized lesion progression without direct remineralization. Both fluoride varnish and resin infiltration are effective non-invasive treatments for WSLs, but their benefits differ. Resin infiltration offers immediate esthetic improvement, while fluoride varnish promotes long-term remineralization and sensitivity reduction.

Keywords: white spot lesions, icon, fluoride varnish, remineralization

Received 2 March 2025 / Accepted 14 April 2025

Introduction

Dental white spot lesions (WSLs) mark the early stage of caries, appearing as white or dark enamel discolorations due to an imbalance in demineralization and remineralization. This weakens dental structure and, if untreated, can lead to cavitated caries requiring invasive treatment. WSLs result from mineral loss due to bacterial acid exposure but can be reversed if the organic matrix remains intact and remineralization conditions are met. Despite their prevalence, no standardized treatment protocol exists, with strategies varying widely in the literature [1,2].

White spots can also result from dental fluorosis, caused by excessive fluoride intake during tooth development, leading to streaks or spots that, while structurally strong, may be an aesthetic concern. Enamel hypoplasia, due to factors like poor nutrition, premature birth, or childhood illness, results in weak enamel prone to damage [3]. Other causes include acidic foods, dry mouth, and genetics, which impact enamel strength. Prevention and treatment focus on good oral hygiene and remineralization rather than just aesthetic masking [4]. Traditional treatments use fluoride applications to promote calcium and phosphate

deposition, while newer biomimetic strategies incorporate bioactive glass, nanohydroxyapatite, and peptides into adhesives, pastes, and topical solutions [5,6].

Remineralization occurs through two main mechanisms: endogenous remineralization, which relies on systemic mineral intake from a nutrient-rich diet (dairy, seafood, proteins, vegetables) as natural sources of calcium, fluoride, and phosphorus, and exogenous remineralization, involving direct application of remineralizing agents like fluoride varnishes, specialized toothpastes, and bioactive solutions [7,8]. Professional oral hygiene, including plaque and calculus removal, enhances treatment efficacy. If untreated, WSLs can progress to deep carious lesions, affecting dentin and potentially reaching the pulp, leading to pulpitis, pain, and endodontic treatment, with severe cases resulting in periodontitis, abscesses, or tooth loss [9,10].

This study evaluates the non-invasive strategies for the management of dental white spot lesions, with a particular focus on the use of Icon vestibular material, a resin infiltration technique designed to arrest lesion progression while preserving tooth structure. By examining its efficacy in comparison to conventional remineralization approaches with fluoride materials, this research seeks to contribute to the development of standardized, evidence-based protocols for WSL management.

* Correspondence to: Alexandra Mihaela Stoica
E-mail: alexandra.stoica@umfst.ro

Thus, the study aims to compare the effectiveness of two non-invasive treatment modalities for managing WSLs, evaluating their impact on esthetic improvement, remineralization, and long-term stability.

Materials and Methods

The study was conducted starting October 2023 to December 2024 and followed a clinical assessment and treatment, evaluating the efficacy of two different non-invasive remineralization strategies for managing dental WSLs using flour-based varnish (GC MI Varnish Intro Pack) and resin infiltration material (Icon Vestibular).

We address 67 patients who were referred to the Odontology Clinic from Integrated Center of Dental Medicine Faculty from Târgu-Mureș, Romania due to their dental sensitivity or dental color modifications or discoloration. All patients were explained the work protocol and asked to sign the consent to participate in the study, so this was added as an inclusion criteria.

The inclusion criteria were: 1) patients with ages at least 12 years old or older with fully erupted permanent teeth; 2) patients with non-cavitated, active WSLs on the buccal surfaces of anterior teeth; 3) patients free from active caries, restorations on the affected teeth, periodontal disease, and genetic disorders; 4) patients who provide written informed consent and be available for all scheduled follow-up evaluations.

Patients who met the inclusion criteria and agreed in participating to the study by signing the informed consent were divided into two groups, each receiving a distinct treatment protocol: 1st group (fluoride group) the patients received topical fluoride varnish applications and the 2nd group (Icon group) the patients who underwent resin infiltration treatment using Icon Vestibular to arrest lesion progression. Each treatment was applied according to manufacturer guidelines and industry standards, both materials were used accordingly after a professional dental brushing and rubber dam isolation. The effectiveness of each treatment and color stability was assessed in the treatment sessions and also compared after 3 months.

The comparative evaluation of the patients in both groups — fluoride varnish group and Icon resin infiltration group — was conducted by a calibrated team of three experienced clinicians from the Odontology Department, each with at least five years of clinical experience in managing enamel lesions. Prior to the study, the evaluators underwent standardized calibration sessions to ensure consistency in lesion assessment and treatment evaluation using clinical photographs as reference. The assessments were carried out under controlled clinical conditions, with each patient seated in a dental unit equipped with standard overhead LED lighting to ensure optimal visibility. Visual inspection of the WSLs was performed using dental loupes with $\times 2.5$ magnification, and clinical photographs were taken before treatment, immediately after, and at the three-month follow-up.

The varnish used for this study was GC MI Varnish Intro Pack from GC^R which is a fluoride varnish that contains Recaldent™ (Casein Phosphopeptide-Amorphous Calcium Phosphate, CPP-ACP) that enhances enamel remineralization. It is a bioactive material designed to deliver fluoride, calcium, and phosphate directly to the tooth surface, promoting the repair of demineralized enamel and it is used in the management of WSLs, the prevention of dental caries in high-risk patients and the treatment of dentin hypersensitivity.

The resin used for group 2 was Icon Vestibular, a low-viscosity, light-cured resin infiltration material designed for the non-invasive treatment of WSLs on the buccal surfaces of teeth. It works by penetrating and sealing the porous enamel structure, preventing further demineralization and improving esthetics. Icon Vestibular is ideal for treating post-orthodontic white spot lesions, early non-cavitated caries, mild fluorosis, and localized enamel hypomineralization, providing an esthetic and minimally invasive solution, but it is not suitable for cavitated lesions, deep caries, severe fluorosis, or severe enamel hypoplasia where more intensive restorative treatments are required. Both Icon Vestibular and GC MI Varnish are non-invasive treatments used to manage WSLs, but they differ significantly in their mechanism of action, composition, and long-term effects.

For the data analysis an independent t-test was used to compare the related measurements from two groups to determine whether there is a significant difference between them (a value of $p < 0.05$ shows significant difference).

This study presents several limitations that must be acknowledged. Firstly, the relatively short follow-up period of three months does not allow for a comprehensive evaluation of the long-term stability and recurrence of white spot lesions (WSLs) post-treatment. Additionally, external factors such as patient diet, saliva composition, and oral hygiene habits were not strictly controlled, which may have influenced the remineralization outcomes.

Results

Out of the initial 67 patients, only 47 met the inclusion criteria, while 20 patients were excluded due to factors outside the study parameters. Among the included patients, the distribution of WSL etiology was as follows: 20 patients (42.5%) had WSLs due to poor oral hygiene, experiencing sensitivity to terminal stimuli; 7 patients (14.9%) developed WSLs post-orthodontic treatment and 20 patients (42.5%) had WSLs following in-office bleaching treatments, also reporting dental sensitivity as Figure 1 shows.

These 47 patients were then randomly assigned into the two treatment groups:

- Fluoride Group (n = 24): received topical fluoride varnish applications (GC MI Varnish).
- Icon Group (n = 23): underwent resin infiltration treatment using Icon Vestibular.

From all the clinical cases included in the study and assessed we obtained the following data regarding the most frequently affected teeth by WSLs (Figure 2).

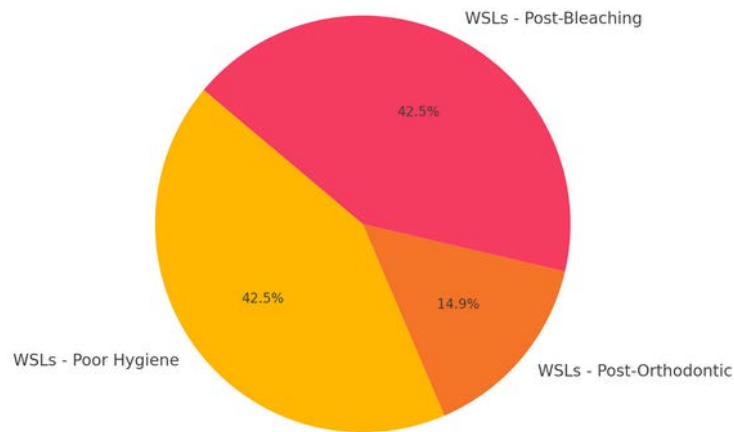


Fig. 1. Distribution of WSL Etiology

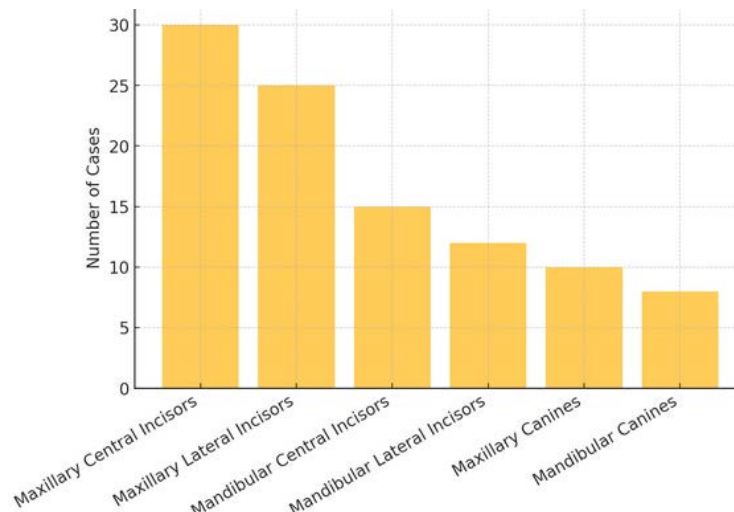


Fig. 2. Distribution of most affected teeth by WSLs

The results regarding the effectiveness of the treatment with both types of materials can be seen in the following Table I and Figure 3.

We present a clinical case of a 12-year-old boy diagnosed with white spot lesions (WSLs) due to poor hygiene and oral respiration, a condition that contributed to enamel

Table I. Treatment results comparison between both types of materials

Assessment Criteria	Group	Findings
Aesthetic Improvement	Icon Group	Immediate and significant reduction in white spot visibility ($p < 0.01$), with a blending effect into surrounding enamel.
Aesthetic Improvement	Fluoride Group	Progressive aesthetic improvement over three months, moderate lesion masking ($p < 0.05$).
WSLs Remineralization	Fluoride Group	Progressive remineralization with significant enamel improvement at three months ($p < 0.05$).
WSLs Remineralization	Icon Group	Stabilization of lesion progression, preventing further demineralization but with limited direct remineralization.
Sensitivity Reduction	Fluoride Group	Notable reduction in dentinal hypersensitivity by the third month ($p < 0.05$).
Sensitivity Reduction	Icon Group	No significant change in sensitivity; resin infiltration acts as a physical sealant without active remineralization properties.

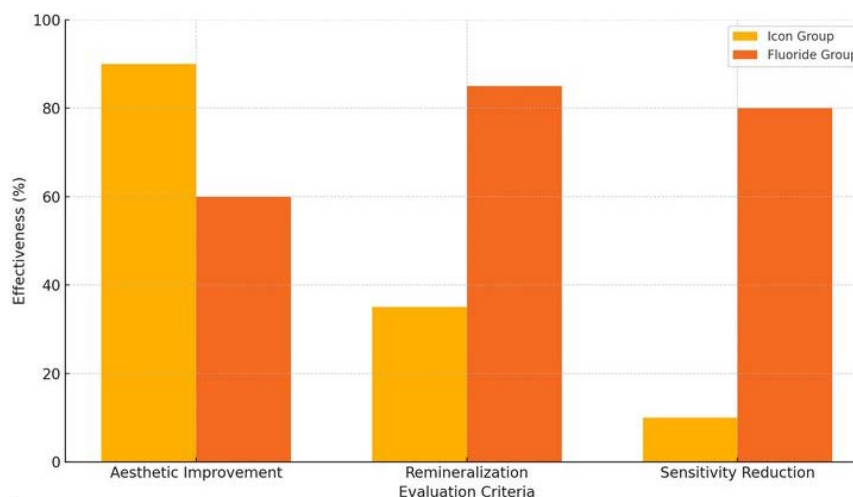


Fig. 3. Graphic representation of the results regarding the effectiveness of both types of materials

demineralization and compromised dental aesthetics. To illustrate the progression and treatment outcome, three sequential images will be included, documenting the initial presentation of WSLs, the application of fluoride varnish treatment, and the final post-treatment result. The therapeutic approach focused on remineralization using fluoride varnish, aiming to enhance enamel integrity and reduce lesion visibility (Figure 4).

We present the clinical case of a 26-year-old woman who developed (WSLs) as a result of orthodontic treatment, a common side effect caused by prolonged plaque accumulation around brackets. To demonstrate the treatment process, sequential images will be presented, showing the initial condition of the WSLs and the post-treatment outcome using Icon kit (Figure 5).

Discussions

Despite all limitations, the study offers significant originality. To our knowledge, it is among the few clinical stud-

ies that directly compare the effects of fluoride varnish (GC MI Varnish) and resin infiltration (Icon Vestibular) on WSLs with a specific focus on esthetic improvement, sensitivity reduction, and remineralization potential. Furthermore, the study highlights WSLs of varying etiology, including post-orthodontic, post-bleaching, and hygiene-related cases, providing a more comprehensive overview of treatment outcomes in real clinical scenarios. The inclusion of clinical case documentation and the analysis of esthetic and functional outcomes contribute to the development of evidence-based protocols for the non-invasive management of WSLs in contemporary dental practice.

The results of this study demonstrate the effectiveness of two non-invasive treatments for managing WSLs: fluoride varnish (GC MI Varnish) and resin infiltration (Icon Vestibular). Both materials contributed to lesion stabilization and esthetic improvement, but their mechanisms of action, immediate effects, and long-term benefits differed significantly. The impact of this study lies in its practical,

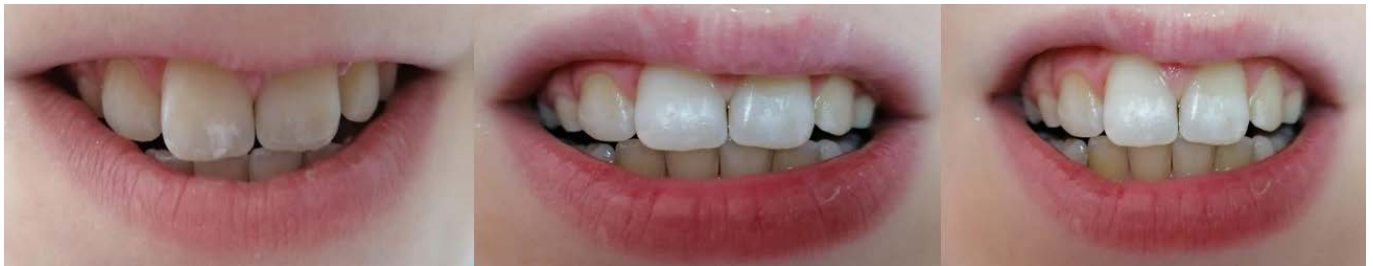

Fig. 4. (1) WSL on central incisor (2) Treatment result using varnish (3) 3 months recall

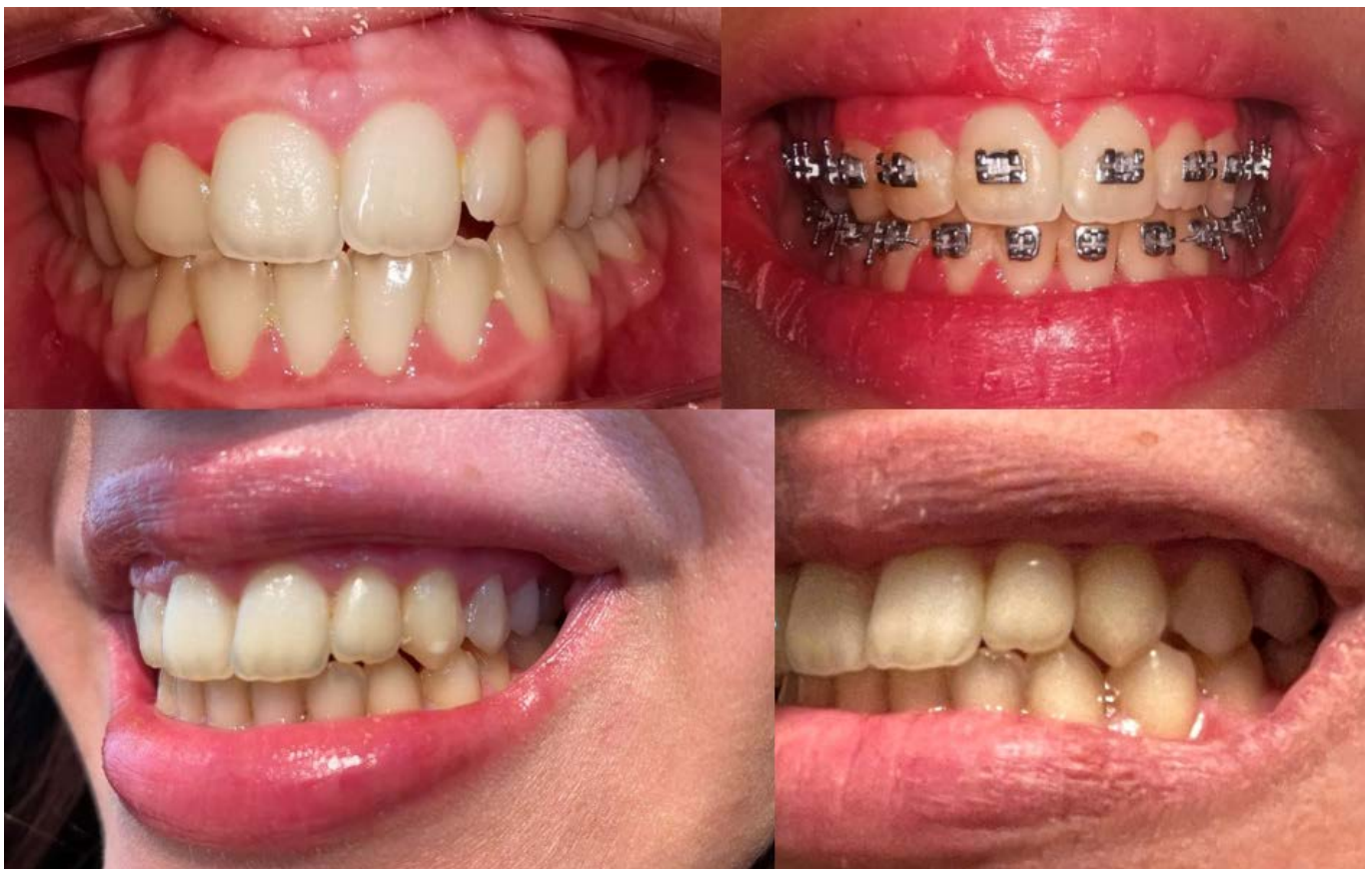

Fig. 5. (1,2,3) WSLs on canine as a result of orthodontic treatment (4) Aesthetic aspect after Icon treatment

side-by-side comparison of two non-invasive treatment modalities — fluoride varnish and resin infiltration — with clearly defined protocols and clinical outcomes. By focusing on esthetic improvement, sensitivity reduction, and remineralization potential, this study offers clinicians evidence-based guidance for selecting the appropriate treatment based on individual case needs.

The Icon Group showed an immediate and statistically significant improvement in the visibility of WSLs ($p < 0.01$), indicating its superiority in aesthetic correction. This aligns with previous studies that support resin infiltration as an effective approach for reducing lesion opacity and improving enamel translucency [8,11]. However, while Icon Vestibular effectively sealed the lesion and prevented further demineralization, its ability to promote enamel remineralization was limited.

In contrast, the Fluoride Group exhibited progressive remineralization over time, with significant enamel improvement observed at three months ($p < 0.05$). This confirms the well-documented role of fluoride in enhancing mineral uptake and restoring enamel [9,12]. When comparing treatment longevity, resin infiltration provided a lasting esthetic improvement, as it integrates with the enamel structure, making WSLs less visible long-term. However, fluoride varnish required repeated applications to maintain its remineralizing benefits, emphasizing the need for ongoing patient compliance and routine dental visits. The findings align with previous reports highlighting fluoride's role in long-term enamel protection, while resin infiltration offers instant esthetic correction but lacks continuous mineral restoration [13,14].

The clinical cases included in this study serve as representative examples of the therapeutic efficacy of non-invasive treatments for WSLs and allow for a more contextualized comparison of the two methods used. The first case, involving a 12-year-old patient with WSLs caused by poor oral hygiene and oral respiration, exemplifies the gradual but effective action of fluoride varnish in promoting remineralization. Over a period of three months, the patient exhibited significant improvement in enamel structure and a visible reduction in lesion opacity. These findings are consistent with literature reports highlighting the role of fluoride and varnishes in enhancing the uptake of calcium and phosphate ions and facilitating the natural repair of subsurface enamel lesions, same scientific contribution offered by Fleming et al. 2023 and Kumar et al., 2023 [15,16].

Conversely, the second case involving a 26-year-old patient with post-orthodontic WSLs demonstrated the immediate esthetic impact of resin infiltration using Icon Vestibular. The procedure significantly masked the lesions, restoring the visual integrity of the enamel in a single session. This result supports findings from Knösel et al. (2020), who reported that resin infiltration provides an effective and durable esthetic solution for orthodontic-induced WSLs, despite offering limited remineralizing properties [6, 17].

Thus, the integration of these clinical outcomes with existing literature reinforces the importance of individualized treatment planning. The clinician must evaluate not only the origin and severity of the WSLs, but also the patient's age, esthetic expectations, and risk of lesion progression in selecting the most appropriate therapy. This tailored approach aligns with the current shift in dentistry toward minimally invasive and patient-centered interventions.

WSLs are particularly prevalent during and after orthodontic treatment, representing one of the most common iatrogenic complications associated with fixed appliances. The brackets and wires used in orthodontics create additional retention sites for plaque accumulation, making effective oral hygiene more difficult. This leads to prolonged exposure of enamel surfaces to demineralizing acids, especially in the cervical areas surrounding brackets. Clinically, post-orthodontic WSLs pose a significant aesthetic concern, particularly in the anterior region, where they are highly visible and can compromise the final outcome of orthodontic therapy. Moreover, their presence may reduce patient satisfaction despite the correction of malocclusion, highlighting the importance of preventive and minimally invasive management. Early detection and treatment of WSLs in orthodontic patients are crucial to prevent progression to cavitated lesions, to avoid more invasive restorative procedures, and to maintain the integrity of the newly aligned dentition. In this context, treatments like resin infiltration (Icon) offer a valuable solution due to their ability to camouflage lesions and halt progression without additional enamel loss.

Despite these positive outcomes, some limitations should be acknowledged. First, the study's follow-up period was limited to three months, preventing a full assessment of long-term treatment durability [18]. Additionally, external factors such as diet, oral hygiene, and individual enamel composition could influence remineralization outcomes, warranting further investigation. Future studies should explore long-term comparisons between these treatments and evaluate combination therapies to maximize both esthetic and remineralization benefits [19,20].

Overall, this study reinforces the importance of tailoring WSL management strategies to individual patient needs. Icon Vestibular is preferable for patients prioritizing immediate esthetic correction, while fluoride varnish remains the gold standard for remineralization and hypersensitivity reduction. A combination approach may provide optimal clinical outcomes, ensuring both long-term enamel health and improved aesthetics [21].

Conclusion

Icon Vestibular provides immediate esthetic improvement by masking white spots, making it ideal for post-orthodontic lesions and mild fluorosis. In contrast, GC MI Varnish offers gradual esthetic enhancement through progressive remineralization, better suited for long-term management rather than instant correction. Fluoride varnish is more ef-

fective for reducing sensitivity, as it delivers fluoride, calcium, and phosphate to strengthen enamel and seal dentinal tubules. Icon Vestibular, while stabilizing lesions, does not provide significant desensitization, making GC MI Varnish the better option for sensitive teeth.

Authors' contribution

AG, AS and DN were responsible for assessment, methodology, supervision and resources. MDM, OES and AMS were responsible for the original draft, writing, data analysis, review and editing the manuscript. KIAC – visualization and validation.

Conflict of interest

None to declare.

References

- Fiorillo L, Laino L, De Stefano R, et al. Systematic Review on White Spot Lesions Treatments. *Eur J Dent.* 2022;16(1):41-52.
- Gousalya V, Prabu D, Raj Mohan M, et al. Systematic Review on the Efficacy of Icon Resin Infiltration on White Spot Lesions. *Int J Oral Care Dent.* 2023;11(1):18-24.
- Cazzolla AP, De Franco AR, Lacaita M, Lacarbonara V. Efficacy of 4-Year Treatment of ICON Infiltration Resin on Postorthodontic White Spot Lesions. *BMJ Case Rep.* 2021;14(1):e225639.
- Sundararajan S, Venkatachalapathy S, Tandon A, Pereira V. Comparison of Therapies of White Spot Lesions: A Systematic Review and Network Meta-Analysis. *BMC Oral Health.* 2023;23(1):1-14.
- Zotti F, Albanese M, Lupi E, et al. Resin Infiltration in Dental Fluorosis Treatment: A 12-Month Follow-Up. *Dent J (Basel).* 2021;9(2):21.
- Knösel M, Eckstein A, Helms HJ. Durability of Esthetic Improvement Following Icon Resin Infiltration of Multibracket-Induced White Spot Lesions Compared with No Therapy over 6 Months: A Single-Center, Split-Mouth, Randomized Clinical Trial. *Am J Orthod Dentofacial.* 2020;158(1):e51-e60.
- Wang Q, Meng Q, Meng J. Minimally Invasive Esthetic Management of Dental Fluorosis: A Case Report. *J Int Med Res.* 2020;48(10):300060520967538.
- Abanto Alvarez J, Rezende KM, Marocho SM, et al. Dental Fluorosis: Exposure, Prevention and Management. *Med Oral Patol Oral Cir Bucal.* 2009;14(2):E103-7.
- Zotti F, Albertini L, Tomizioli N, et al. Resin Infiltration in Dental Fluorosis Treatment-1-Year Follow-Up. *Medicina (Kaunas).* 2020;57(1):22.
- Rodd HD, Graham A, Tajmehr N, et al. Molar Incisor Hypomineralisation: Current Knowledge and Practice. *Int Dent J.* 2021;71(3):178-184.
- Denis M, Atlan A, Vennat E, et al. White Defects on Enamel: Diagnosis and Anatomopathology: Two Essential Factors for Proper Treatment (Part 1). *Int Orthod.* 2013;11(2):139-165.
- Muñoz MA, Arana-Gordillo LA, Gomes GM, et al. Alternative Esthetic Management of Fluorosis and Hypoplasia Stains: Blending Effect Obtained with Resin Infiltration Techniques. *J Esthet Restor Dent.* 2013;25(1):32-39.
- Nahsan FP, Da Silva LM, Baseggio W, et al. Conservative Approach for a Clinical Resolution of Enamel White Spot Lesions. *Quintessence Int.* 2011;42:423-426.
- Perdigão J. Resin Infiltration of Enamel White Spot Lesions: An Ultramorphological Analysis. *J Esthet Restor Dent.* 2020;32(3):317-324.
- Fleming PS, Koletsi D. Prevention of White Spot Lesions with Fluoride Varnish During Orthodontic Treatment: A Systematic Review and Meta-Analysis. *Eur J Orthod.* 2023;45(5):485-493.
- Kumar S, Kumar A. Fluoride-Releasing Materials to Prevent White Spot Lesions Around Orthodontic Brackets: A Systematic Review. *Braz Dent J.* 2023;34(1):1-8.
- Brescia AV, Montesani L, Fusaroli D, et al. Management of Enamel Defects with Resin Infiltration Techniques: Two Years Follow Up Retrospective Study. *Dent J (Basel).* 2022;9(9):13-65.
- Alkis H, Turkkahraman H, Adanir N. Microleakage under Orthodontic Brackets Bonded with Different Adhesive Systems. *Eur J Dent.* 2015;9(1):117-121.
- Ali A, Ismail H, Amin K. Effect of Nanosilver Mouthwash on Prevention of White Spot Lesions in Patients Undergoing Fixed Orthodontic Treatment-A Randomized Double-Blind Clinical Trial. *J Dent Sci.* 2022;17(1):249-255.
- Attar HJ, Hacham I. Chlorhexidine Effect on Color of Treated White Spot Lesion with Remineralization Materials (Fluoride Varnish, Tooth Mouse). *J Oral Dent Res.* 2020;7(1):30-36.
- Heymann GC, Grauer D. A Contemporary Review of White Spot Lesions in Orthodontics: White Spot Lesions in Orthodontics. *J Esthet Restor Dent.* 2013;25(2):85-95.